

SAMPLE TEST QUESTIONS

Step 1



**This booklet was updated February 2021.
For Public Release**

Copyright © 2021 by the Federation of State Medical Boards of the United States, Inc. (FSMB), and National Board of Medical Examiners® (NBME®). All rights reserved. Printed in the United States of America. The United States Medical Licensing Examination (USMLE®) is a joint program of the FSMB and NBME.

CONTENTS

USMLE Step 1 Test Question Formats	3
Introduction to USMLE Step 1 Sample Test Questions	4
USMLE Laboratory Values	5
USMLE Step 1 Sample Test Questions.....	8
Answer Form for USMLE Step 1 Sample Test Questions.....	48
Answer Key for USMLE Step 1 Sample Test Questions.....	49

Single-Item Questions

A single patient-centered vignette is associated with one question followed by four or more response options. The response options are lettered (A, B, C, D, E). A portion of the questions require interpretation of graphic or pictorial materials. You are required to select the best answer to the question. Other options may be partially correct, but there is only ONE BEST answer. This is the traditional, most frequently used multiple-choice question format on the examination.

Strategies for Answering Single One-Best-Answer Test Questions

The following are strategies for answering one-best-answer items:

- Read each patient vignette and question carefully. It is important to understand what is being asked.
- Try to generate an answer and then look for it in the response option list.
- Alternatively, read each response option carefully, eliminating those that are clearly incorrect.
- Of the remaining options, select the one that is most correct.
- If unsure about an answer, it is better to guess since unanswered questions are automatically counted as wrong answers.

Example Item

A 32-year-old woman with type 1 diabetes mellitus has had progressive renal failure during the past 2 years. She has not yet started dialysis. Examination shows no abnormalities. Her hemoglobin concentration is 9 g/dL, hematocrit is 28%, and mean corpuscular volume is 94 μm^3 . A blood smear shows normochromic, normocytic cells. Which of the following is the most likely cause?

- | | |
|-----------------------------------|--------------------------------|
| (A) Acute blood loss | (F) Microangiopathic hemolysis |
| (B) Chronic lymphocytic leukemia | (G) Polycythemia vera |
| (C) Erythrocyte enzyme deficiency | (H) Sickle cell disease |
| (D) Erythropoietin deficiency | (I) Sideroblastic anemia |
| (E) Immuno-hemolysis | (J) β -Thalassemia trait |

(Answer: D)

NOTE: Some item types that appear on the Step 1 examination are NOT depicted in the sample items provided in this booklet, eg, items with multimedia features, such as audio. Also, when additional item formats are added to the exam, notice will be provided at the USMLE website: <http://www.usmle.org>. You must monitor the website to stay informed about the types of items that occur in the exam, and you must practice with the downloadable sample test items available on the USMLE website to be fully prepared for the examination.

INTRODUCTION TO USMLE STEP 1 SAMPLE TEST QUESTIONS

The following pages include 119 sample test questions. Most of these questions are the same as those you can install on your computer from the USMLE website. Please note that reviewing the sample questions as they appear on pages 8–47 is not a substitute for practicing with the test software. You should download and run the Step 1 tutorial and practice test items that are provided on the USMLE website well before your test date. The sample materials available on the USMLE website include an additional item with associated audio findings that does not appear in this booklet. You should become familiar with this item format that will be used in the actual examination.

Although the sample questions exemplify content on the Step 1 examination overall, they may not reflect the content coverage on individual examinations. In the actual examination, questions will be presented in random order; they will not be grouped according to specific content. The questions will be presented one at a time in a format designed for easy on-screen reading, including use of the USMLE Laboratory Values table (included here on pages 5–7) and some pictorials. Photographs, charts, and x-rays in this booklet are not of the same quality as the pictorials used in the actual examination. In addition, you will be able to adjust the brightness and contrast of pictorials on the computer screen.

To take the following sample test questions as they would be timed in the actual examination, you should allow a maximum of 1 hour for each 40-item block, and a maximum of 58 minutes, 30 seconds, for the 39-item block, for a total of 2 hours, 58 minutes, 30 seconds. Please note that the third block has 39 items instead of 40 because the multimedia item has been removed, and the recommended time to complete the block has been adjusted accordingly. Please be aware that most examinees perceive the time pressure to be greater during an actual examination. All examinees are strongly encouraged to practice with the downloadable version to become familiar with all item formats and exam timing. An answer form for recording answers is provided on page 48. An answer key is provided on page 49. In the actual examination, answers will be selected on the screen; no answer form will be provided.

	<u>Reference Range</u>	<u>SI Reference Intervals</u>
SERUM		
General Chemistry:		
Electrolytes		
Sodium (Na ⁺)	136–146 mEq/L	136–146 mmol/L
Potassium (K ⁺)	3.5–5.0 mEq/L	3.5–5.0 mmol/L
Chloride (Cl ⁻)	95–105 mEq/L	95–105 mmol/L
Bicarbonate (HCO ₃ ⁻)	22–28 mEq/L	22–28 mmol/L
Urea nitrogen	7–18 mg/dL	2.5–6.4 mmol/L
Creatinine	0.6–1.2 mg/dL	53–106 μmol/L
Glucose	Fasting: 70–100 mg/dL Random, non-fasting: <140 mg/dL	3.8–5.6 mmol/L <7.77 mmol/L
Calcium	8.4–10.2 mg/dL	2.1–2.6 mmol/L
Magnesium (Mg ²⁺)	1.5–2.0 mg/dL	0.75–1.0 mmol/L
Phosphorus (inorganic)	3.0–4.5 mg/dL	1.0–1.5 mmol/L
Hepatic:		
Alanine aminotransferase (ALT)	10–40 U/L	10–40 U/L
Aspartate aminotransferase (AST)	12–38 U/L	12–38 U/L
Alkaline phosphatase	25–100 U/L	25–100 U/L
Amylase	25–125 U/L	25–125 U/L
Bilirubin, Total // Direct	0.1–1.0 mg/dL // 0.0–0.3 mg/dL	2–17 μmol/L // 0–5 μmol/L
Proteins, total	6.0–7.8 g/dL	60–78 g/L
Albumin	3.5–5.5 g/dL	35–55 g/L
Globulin	2.3–3.5 g/dL	23–35 g/L
Lipids:		
Cholesterol		
Total	Normal: <200 mg/dL High: >240 mg/dL	<5.2 mmol/L >6.2 mmol/L
HDL	40–60 mg/dL	1.0–1.6 mmol/L
LDL	<160 mg/dL	<4.2 mmol/L
Triglycerides	Normal: <150 mg/dL Borderline: 151–199 mg/dL	<1.70 mmol/L 1.71–2.25 mmol/L
Iron Studies:		
Ferritin	Male: 20–250 ng/mL Female: 10–120 ng/mL	20–250 μg/L 10–120 μg/L
Iron	Male: 65–175 μg/dL Female: 50–170 μg/dL	11.6–31.3 μmol/L 9.0–30.4 μmol/L
Total iron-binding capacity	250–400 μg/dL	44.8–71.6 μmol/L
Transferrin	200–360 mg/dL	2.0–3.6 g/L

USMLE Laboratory Values (continued)

	<u>Reference Range</u>	<u>SI Reference Intervals</u>
Endocrine:		
Follicle-stimulating hormone	Male: 4–25 mIU/mL Female: premenopause 4–30 mIU/mL midcycle peak 10–90 mIU/mL postmenopause 40–250 mIU/mL	4–25 IU/L 4–30 IU/L 10–90 IU/L 40–250 IU/L
Luteinizing hormone	Male: 6–23 mIU/mL Female: follicular phase 5–30 mIU/mL midcycle 75–150 mIU/mL postmenopause 30–200 mIU/mL	6–23 IU/L 5–30 IU/L 75–150 IU/L 30–200 IU/L
Growth hormone - arginine stimulation	Fasting: <5 ng/mL Provocative stimuli: >7 ng/mL	<5 µg/L >7 µg/L
Prolactin (hPRL)	Male: <17 ng/mL Female: <25 ng/mL	<17 µg/L <25 µg/L
Cortisol	0800 h: 5–23 µg/dL 1600 h: 3–15 µg/dL 2000 h: <50% of 0800 h	138–635 nmol/L 82–413 nmol/L Fraction of 0800 h: <0.50
TSH	0.4–4.0 µU/mL	0.4–4.0 mIU/L
Triiodothyronine (T ₃) (RIA)	100–200 ng/dL	1.5–3.1 nmol/L
Triiodothyronine (T ₃) resin uptake	25%–35%	0.25–0.35
Thyroxine (T ₄)	5–12 µg/dL	64–155 nmol/L
Free T ₄	0.9–1.7 ng/dL	12.0–21.9 pmol/L
Thyroidal iodine (¹²³ I) uptake	8%–30% of administered dose/24 h	0.08–0.30/24 h
Intact PTH	10–60 pg/mL	10–60 ng/L
17-Hydroxycorticosteroids	Male: 3.0–10.0 mg/24 h Female: 2.0–8.0 mg/24 h	8.2–27.6 µmol/24 h 5.5–22.0 µmol/24 h
17-Ketosteroids, total	Male: 8–20 mg/24 h Female: 6–15 mg/24 h	28–70 µmol/24 h 21–52 µmol/24 h
Immunoglobulins:		
IgA	76–390 mg/dL	0.76–3.90 g/L
IgE	0–380 IU/mL	0–380 kIU/L
IgG	650–1500 mg/dL	6.5–15.0 g/L
IgM	50–300 mg/dL	0.5–3.0 g/L
Other, serum:		
Creatinine clearance	Male: 97–137 mL/min Female: 88–128 mL/min	97–137 mL/min 88–128 mL/min
Creatine kinase	Male: 25–90 U/L Female: 10–70 U/L	25–90 U/L 10–70 U/L
Lactate dehydrogenase	45–200 U/L	45–200 U/L
Osmolality	275–295 mOsmol/kg H ₂ O	275–295 mOsmol/kg H ₂ O
Uric acid	3.0–8.2 mg/dL	0.18–0.48 mmol/L
GASES, ARTERIAL BLOOD (ROOM AIR)		
PO ₂	75–105 mm Hg	10.0–14.0 kPa
PCO ₂	33–45 mm Hg	4.4–5.9 kPa
pH	7.35–7.45	[H ⁺] 36–44 nmol/L
CEREBROSPINAL FLUID		
Cell count	0–5/mm ³	0–5 × 10 ⁶ /L
Chloride	118–132 mEq/L	118–132 mmol/L
Gamma globulin	3%–12% total proteins	0.03–0.12
Glucose	40–70 mg/dL	2.2–3.9 mmol/L
Pressure	70–180 mm H ₂ O	70–180 mm H ₂ O
Proteins, total	<40 mg/dL	<0.40 g/L

Continued on Next Page

USMLE Laboratory Values (continued)

	<u>Reference Range</u>	<u>SI Reference Intervals</u>
HEMATOLOGIC		
<i>Complete Blood Count:</i>		
Hematocrit	Male: 41%–53% Female: 36%–46%	0.41–0.53 0.36–0.46
Hemoglobin, blood	Male: 13.5–17.5 g/dL Female: 12.0–16.0 g/dL	135–175 g/L 120–160 g/L
Mean corpuscular hemoglobin (MCH)	25–35 pg/cell	0.39–0.54 fmol/cell
Mean corpuscular hemoglobin conc. (MCHC)	31%–36% Hb/cell	4.8–5.6 mmol Hb/L
Mean corpuscular volume (MCV)	80–100 μm^3	80–100 fL
Volume		
Plasma	Male: 25–43 mL/kg Female: 28–45 mL/kg	0.025–0.043 L/kg 0.028–0.045 L/kg
Red cell	Male: 20–36 mL/kg Female: 19–31 mL/kg	0.020–0.036 L/kg 0.019–0.031 L/kg
Leukocyte count (WBC)	4500–11,000/mm ³	$4.5\text{--}11.0 \times 10^9/\text{L}$
Neutrophils, segmented	54%–62%	0.54–0.62
Neutrophils, bands	3%–5%	0.03–0.05
Lymphocytes	25%–33%	0.25–0.33
Monocytes	3%–7%	0.03–0.07
Eosinophils	1%–3%	0.01–0.03
Basophils	0%–0.75%	0.00–0.0075
Platelet count	150,000–400,000/mm ³	$150\text{--}400 \times 10^9/\text{L}$
<i>Coagulation:</i>		
Partial thromboplastin time (PTT) (activated)	25–40 seconds	25–40 seconds
Prothrombin time (PT)	11–15 seconds	11–15 seconds
D-Dimer	$\leq 250 \text{ ng/mL}$	$\leq 1.4 \text{ nmol/L}$
<i>Other, Hematologic:</i>		
Reticulocyte count	0.5%–1.5%	0.005–0.015
Erythrocyte count	Male: 4.3–5.9 million/mm ³ Female: 3.5–5.5 million/mm ³	$4.3\text{--}5.9 \times 10^{12}/\text{L}$ $3.5\text{--}5.5 \times 10^{12}/\text{L}$
Erythrocyte sedimentation rate (Westergren)	Male: 0–15 mm/h Female: 0–20 mm/h	0–15 mm/h 0–20 mm/h
CD4+ T-lymphocyte count	$\geq 500/\text{mm}^3$	$\geq 0.5 \times 10^9/\text{L}$
Troponin I	$\leq 0.04 \text{ ng/mL}$	$\leq 0.04 \mu\text{g/L}$
<i>Endocrine:</i>		
Hemoglobin A _{1c}	$\leq 6\%$	$\leq 42 \text{ mmol/mol}$
URINE		
Calcium	100–300 mg/24 h	2.5–7.5 mmol/24 h
Osmolality	50–1200 mOsmol/kg H ₂ O	50–1200 mOsmol/kg H ₂ O
Oxalate	8–40 $\mu\text{g/mL}$	90–445 $\mu\text{mol/L}$
Proteins, total	$< 150 \text{ mg/24 h}$	$< 0.15 \text{ g/24 h}$
BODY MASS INDEX (BMI)		
	Adult: 19–25 kg/m ²	

USMLE STEP 1 SAMPLE TEST QUESTIONS

BLOCK 1, ITEMS 1-40

1. A 67-year-old woman with congenital bicuspid aortic valve is admitted to the hospital because of a 2-day history of fever and chills. Current medication is lisinopril. Temperature is 38.0°C (100.4°F), pulse is 90/min, respirations are 20/min, and blood pressure is 110/70 mm Hg. Cardiac examination shows a grade 3/6 systolic murmur that is best heard over the second right intercostal space. Blood culture grows viridans streptococci susceptible to penicillin. In addition to penicillin, an antibiotic synergistic to penicillin is administered that may help shorten the duration of this patient's drug treatment. Which of the following is the most likely mechanism of action of this additional antibiotic on bacteria?
- (A) Binding to DNA-dependent RNA polymerase
 - (B) Binding to the 30S ribosomal protein
 - (C) Competition with *p*-aminobenzoic acid
 - (D) Inhibition of dihydrofolate reductase
 - (E) Inhibition of DNA gyrase
2. A 12-year-old girl is brought to the physician because of a 2-month history of intermittent yellowing of the eyes and skin. Physical examination shows no abnormalities except for jaundice. Her serum total bilirubin concentration is 3 mg/dL, with a direct component of 1 mg/dL. Serum studies show a haptoglobin concentration and AST and ALT activities that are within the reference ranges. There is no evidence of injury or exposure to toxins. Which of the following additional findings is most likely in this patient?
- (A) Decreased activity of UDP glucuronosyltransferase
 - (B) Gallstones
 - (C) Increased hemolysis
 - (D) Increased serum alkaline phosphatase activity
 - (E) Ineffective erythropoiesis
3. During an experiment, drug X is added to a muscle bath containing a strip of guinea pig intestinal smooth muscle. Agonists are added to the bath, and the resultant effects on muscle tension are shown in the table.

Agonist	Muscle Tension Before Drug X (g)	Muscle Tension After Drug X (g)
Vehicle	6.0	6.1
Acetylcholine	11.3	18.5
Norepinephrine	4.1	4.2

Which of the following types of drugs is most likely to produce effects most similar to those of drug X?

- (A) α_1 -Adrenergic antagonist
- (B) β -Adrenergic antagonist
- (C) Cholinesterase inhibitor
- (D) Monoamine oxidase inhibitor
- (E) Muscarinic antagonist

4. A 30-year-old woman, gravida 2, para 0, aborta 1, at 28 weeks' gestation comes to the office for a prenatal visit. She has had one previous pregnancy resulting in a spontaneous abortion at 12 weeks' gestation. Today, her vital signs are within normal limits. Physical examination shows a uterus consistent in size with a 28-week gestation. Fetal ultrasonography shows a male fetus with no abnormalities. Her blood group is O, Rh-negative. The father's blood group is B, Rh-positive. The physician recommends administration of Rh_o(D) immune globulin to the patient. This treatment is most likely to prevent which of the following in this mother?

- (A) Development of natural killer cells
- (B) Development of polycythemia
- (C) Formation of antibodies to RhD
- (D) Generation of IgM antibodies from fixing complement in the fetus
- (E) Immunosuppression caused by RhD on erythrocytes from the fetus

5. A 55-year-old man is brought to the emergency department because of shortness of breath and confusion for 4 hours. He has hypertension and chronic kidney disease requiring hemodialysis. An ECG shows low voltage with electrical alternans. Physical examination is most likely to show which of the following findings?

	Blood Pressure (mm Hg)	Pulse (/min)	Jugular Venous Pressure	Pulsus Paradoxus
(A)	85/60	120	increased	increased
(B)	85/60	120	increased	normal
(C)	85/60	120	normal	normal
(D)	120/80	80	increased	increased
(E)	120/80	80	normal	increased
(F)	120/80	80	normal	normal

6. A 52-year-old woman begins pharmacotherapy after being diagnosed with type 2 diabetes mellitus. Four weeks later, her hepatic glucose output is decreased, and target tissue glucose uptake and utilization are increased. Which of the following drugs was most likely prescribed for this patient?

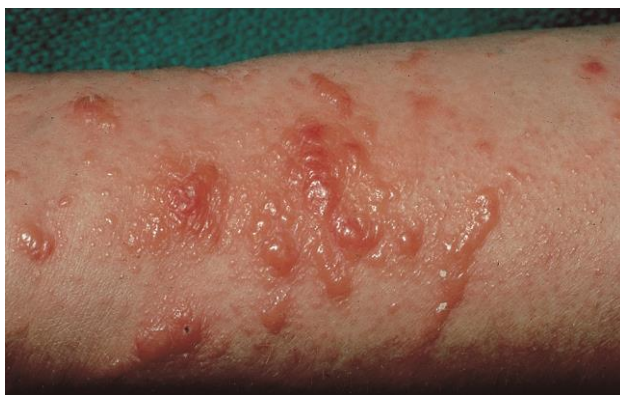- (A) Acarbose
- (B) Glyburide
- (C) Metformin
- (D) Nateglinide
- (E) Repaglinide

7. An asymptomatic 44-year-old man is found to have HIV infection during routine screening prior to donating blood. A complete blood count done at the time of the screening shows:

Hemoglobin	10 g/dL
Hematocrit	30%
Leukocyte count	4600/mm ³
Platelet count	15,000/mm ³
Prothrombin time	12 sec (INR=1.1)
Partial thromboplastin time	23 sec

Which of the following physical findings is most likely in this patient?

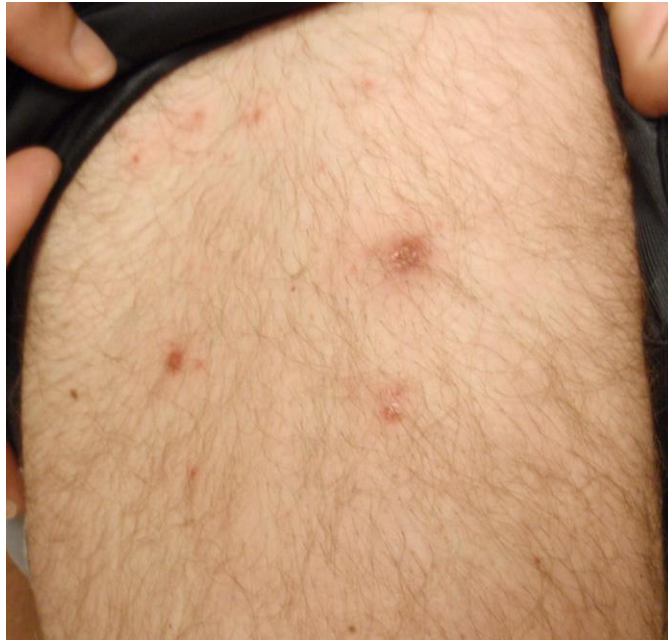- (A) Deep venous thrombosis
 - (B) Hemarthrosis
 - (C) Petechiae
 - (D) Subungual hemorrhage
 - (E) Visceral hematoma
-
8. A 23-year-old woman with bone marrow failure is treated with a large dose of rabbit antithymocyte globulin. Ten days later, she develops fever, lymphadenopathy, arthralgias, and erythema on her hands and feet. Which of the following is the most likely cause of these symptoms?
- (A) Cytokine secretion by natural killer cells
 - (B) Eosinophil degranulation
 - (C) Immune complex deposition in tissues
 - (D) Polyclonal T-lymphocyte activation
 - (E) Widespread apoptosis of B lymphocytes
9. After being severely beaten and sustaining a gunshot wound to the abdomen, a 42-year-old woman undergoes resection of a perforated small bowel. During the operation, plastic reconstruction of facial fractures, and open reduction and internal fixation of the left femur are also done. Thirty-six hours postoperatively, she is awake but not completely alert. She is receiving intravenous morphine via a patient-controlled pump. She says that she needs the morphine to treat her pain, but she is worried that she is becoming addicted. She has no history of substance use disorder. She drinks one to two glasses of wine weekly. Which of the following initial actions by the physician is most appropriate?
- (A) Reassure the patient that her chance of becoming addicted to narcotics is minuscule
 - (B) Maintain the morphine, but periodically administer intravenous naloxone
 - (C) Switch the patient to oral acetaminophen as soon as she can take medication orally
 - (D) Switch the patient to intramuscular lorazepam
 - (E) Switch the patient to intravenous phenobarbital



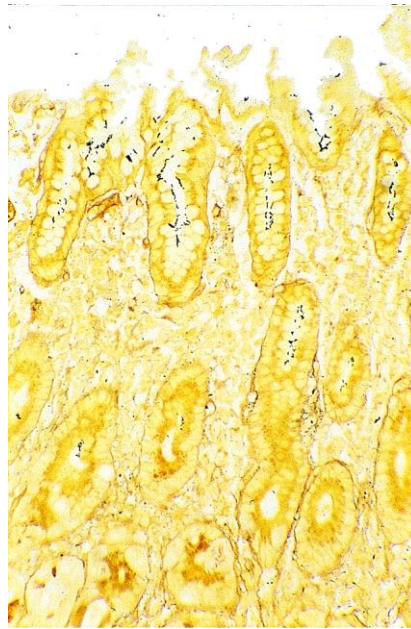
10. A 22-year-old woman comes to the office because of a 4-day history of an itchy, red rash on her right arm. She has no history of major medical illness and takes no medications. She says she has recently used a new hair dye. She is 165 cm (5 ft 5 in) tall and weighs 61 kg (135 lb); BMI is 23 kg/m². Her temperature is 37.0°C (98.6°F), pulse is 70/min, respirations are 22/min, and blood pressure is 115/70 mm Hg. Examination of the right forearm shows the findings in the photograph. Which of the following ligand → receptor pairs most likely played a primary role in the proliferation of the T lymphocytes present at the site of the rash in this patient?
- (A) CD2 on T lymphocytes → intercellular adhesion molecule (ICAM)-3 on epidermal Langerhans cells
 - (B) CD28 on T lymphocytes → CD80 on epidermal Langerhans cells
 - (C) CD40L on T lymphocytes → CD40 on epidermal Langerhans cells
 - (D) CD45 on T lymphocytes → CD28 on epidermal Langerhans cells
 - (E) Lymphocyte function-associated antigen-1 on T lymphocytes → ICAM1 on epidermal Langerhans cells
-
11. Six healthy subjects participate in a study of muscle metabolism during which hyperglycemia and hyperinsulinemia is induced. Muscle biopsy specimens obtained from the subjects during the resting state show significantly increased concentrations of malonyl-CoA. The increased malonyl-CoA concentration most likely directly inhibits which of the following processes in these subjects?
- (A) Fatty acid oxidation
 - (B) Fatty acid synthesis
 - (C) Gluconeogenesis
 - (D) Glycogenolysis
 - (E) Glycolysis
 - (F) Oxidative phosphorylation
12. Over 1 year, a study is conducted to assess the antileukemic activity of a new tyrosine kinase inhibitor in patients with chronic myeloid leukemia in blast crisis. All patients enrolled in the study are informed that they would be treated with the tyrosine kinase inhibitor. They are assigned to successive dose cohorts of 300 to 1000 mg/day of the drug. Six to eight patients are assigned to each dose. Treatment efficacy is determined based on the results of complete blood counts and bone marrow assessments conducted regularly throughout the study. This study is best described as which of the following?
- (A) Case-control study
 - (B) Crossover study
 - (C) Open-labeled clinical trial
 - (D) Randomized clinical trial
 - (E) Single-blind, randomized, controlled trial

13. A 63-year-old man is brought to the emergency department because of a 4-day history of increasingly severe left leg pain and swelling of his left calf. He also has a 1-month history of increasingly severe upper midthoracic back pain. During this time, he has had a 9-kg (20-lb) weight loss despite no change in appetite. He has no history of major medical illness. His only medication is ibuprofen. He is 180 cm (5 ft 11 in) tall and weighs 82 kg (180 lb); BMI is 25 kg/m². His vital signs are within normal limits. On examination, lower extremity pulses are palpable bilaterally. The remainder of the physical examination shows no abnormalities. An x-ray of the thoracic spine shows no abnormalities. A CT scan of the abdomen shows a 3-cm mass in the body of the pancreas; there are liver metastases and encasement of the superior mesenteric artery. Ultrasonography of the left lower extremity shows a femoropopliteal venous clot. Which of the following is the most likely cause of this patient's symptoms?
- (A) Carcinoid syndrome
 - (B) Hypercoagulability from advanced malignancy
 - (C) Multiple endocrine neoplasia
 - (D) Splenic artery aneurysm and embolic disease of the left lower extremity
 - (E) Superior mesenteric artery syndrome
14. A 40-year-old woman comes to the physician because of a 6-month history of increased facial hair growth. Her last menstrual period was 4 months ago. She is 165 cm (5 ft 5 in) tall and weighs 70 kg (154 lb); BMI is 26 kg/m². Her pulse is 80/min, and blood pressure is 130/82 mm Hg. Physical examination shows temporal balding and coarse dark hair on the upper lip and chin. Pelvic examination shows clitoral enlargement. Her serum testosterone concentration is increased. Serum concentrations of androstenedione, dehydroepiandrosterone, and urinary 17-ketosteroids are within the reference ranges. Ultrasonography of the pelvis shows a 12-cm ovarian mass. Which of the following best describes this mass?
- (A) Granulosa tumor
 - (B) Ovarian carcinoid
 - (C) Sertoli-Leydig tumor
 - (D) Teratoma
 - (E) Thecoma
15. A 35-year-old man comes to the physician because of pain and swelling of his right arm where he scraped it on a tree branch 2 days ago. His temperature is 38.3°C (101°F). Examination of the right forearm shows edema around a fluctuant erythematous lesion at the site of trauma. The area is extremely tender to palpation. Which of the following is most likely the primary mechanism of the development of edema in this patient?
- (A) Degranulation of eosinophils
 - (B) Disruption of vascular basement membranes
 - (C) Increased hydrostatic pressure
 - (D) Release of thromboxane
 - (E) Separation of endothelial junctions
16. A 12-year-old boy is brought to the physician because of a 2-month history of headaches and a 6-day history of nausea and vomiting. Funduscopic examination shows bilateral papilledema. He walks with a broad-based gait. An MRI of the brain shows a tumor in the pineal region compressing the brain stem and leading to hydrocephalus. This patient most likely has impairment of which of the following oculomotor functions?
- (A) Abduction
 - (B) Horizontal pursuit
 - (C) Optokinetic nystagmus
 - (D) Upward gaze
 - (E) Vestibulo-ocular reflex

17. A 52-year-old man comes to the emergency department because of a 1-day history of nausea, vomiting, and right-sided abdominal pain that radiates to his back. He has not had fever or increased urinary frequency. He has a history of type 2 diabetes mellitus, hyperlipidemia, hypertension, and atrial fibrillation. Current medications are atorvastatin, glyburide, hydrochlorothiazide, lisinopril, and warfarin. He smoked 1½ packs of cigarettes daily for 35 years until he quit 6 months ago. He has had no recent alcoholic beverage or illicit drug use. He is 188 cm (6 ft 2 in) tall and weighs 109 kg (240 lb); BMI is 31 kg/m². Temperature is 36.4°C (97.6°F), pulse is 88/min, respirations are 20/min, and blood pressure is 165/92 mm Hg. Pulse oximetry on room air shows an oxygen saturation of 96%. Physical examination discloses right upper quadrant and flank tenderness but no rebound tenderness or guarding. CT scan of the abdomen with and without contrast shows an enlarged right kidney and wedge-shaped areas of hypodensity; there is no evidence of nephrolithiasis. Which of the following is the strongest predisposing risk factor for this patient's condition?
- (A) Atrial fibrillation
 - (B) Hyperlipidemia
 - (C) Hypertension
 - (D) Past smoking history
 - (E) Type 2 diabetes mellitus
-



18. A 24-year-old man comes to the office because of a 2-day history of a red, itchy rash on his buttocks and legs. Four days ago, he returned from a cruise to the Caribbean, during which he swam in the ship's pool and used the hot tub. He appears well. His vital signs are within normal limits. Physical examination shows the findings in the photograph. The infectious agent causing these findings most likely began to proliferate in which of the following locations?
- (A) Apocrine gland
 - (B) Dermis
 - (C) Eccrine gland
 - (D) Hair follicle
 - (E) Sebaceous gland



19. An otherwise healthy 45-year-old man comes to the physician because of a 3-week history of progressive epigastric heartburn and a 4.5-kg (10-lb) weight loss. The pain tends to be more severe at night and occurs 1 to 3 hours after meals during the day. He has had similar episodes with lesser intensity during the past year. Abdominal examination shows tenderness to deep palpation. Test of the stool for occult blood is positive. Endoscopy shows a bleeding 3-cm ulcer in the antrum of the stomach. A photomicrograph of Steiner silver-stained tissue (400x) from a biopsy of the gastric mucosa adjacent to the ulcer is shown. Which of the following processes is most likely to be involved?
- (A) Elaboration of proteases and urease with local tissue destruction
 - (B) Hyperacidity and gastric ulcer development
 - (C) Ingestion of preformed toxins in contaminated well water
 - (D) Spirochete invasion of gastric cells
-
20. A 14-year-old boy is brought to the emergency department after being hit with a baseball bat on the lateral side of his leg immediately below the knee. He is unable to dorsiflex his foot. Which of the following nerves is most likely injured?
- (A) Common fibular (peroneal)
 - (B) Femoral
 - (C) Obturator
 - (D) Sural
 - (E) Tibial
21. A 26-year-old woman is brought to the emergency department because of an 8-hour history of severe back and abdominal pain and mild but persistent vaginal bleeding. Ultrasonography of the abdomen shows a 2-cm ectopic pregnancy in the ampulla. The ampulla has ruptured into the surrounding tissue. Fluid from this rupture will most likely be found in which of the following locations?
- (A) Lesser peritoneal cavity
 - (B) Mesometrium
 - (C) Pouch of Douglas
 - (D) Uterine cavity
 - (E) Vagina

22. A 46-year-old woman with active ankylosing spondylitis comes to the office for a follow-up examination. The use of various conventional nonsteroidal anti-inflammatory drugs has been ineffective. Sulfasalazine treatment also has not resulted in improvement. The most appropriate next step in treatment is administration of a drug that inhibits which of the following?
- (A) CD20
 - (B) Cyclooxygenase-2
 - (C) Cytotoxic T-lymphocyte antigen 4
 - (D) Epidermal growth factor
 - (E) Interleukin-1 (IL-1)
 - (F) Tumor necrosis factor α
23. A 55-year-old man comes to the physician because of a 2-week history of recurrent, widespread blister formation. Physical examination shows lesions that are most numerous in the flexural areas including the axillae and groin. The blisters do not break easily, and there are no oral lesions. These blisters are most likely the result of adhesion failure involving which of the following?
- (A) Basement membrane
 - (B) Dermal papillae
 - (C) Langerhans cells
 - (D) Melanocytes
 - (E) Merkel cells
24. A 17-year-old girl is brought to the emergency department 30 minutes after her boyfriend found her unconscious next to an empty bottle of acetaminophen. It is suspected that she ingested the tablets approximately 12 hours ago. Her serum acetaminophen concentration is markedly increased. Treatment with activated charcoal and acetylcysteine is initiated. Approximately 48 hours later, the patient develops jaundice, and her serum AST activity is 3000 U/L. Which of the following best explains the jaundice in this patient?
- (A) Activation of biliverdin reductase
 - (B) Decreased bilirubin conjugation
 - (C) Decreased generation of urobilinogen
 - (D) Increased hemolysis
 - (E) Increased serum glutathione concentration
25. A 72-year-old woman comes to the physician because of a 3-day history of fever, shortness of breath, difficulty swallowing, chest pain, and cough. She is frail. Physical examination shows tachypnea and equal pulses bilaterally. Percussion of the chest shows dullness over the right lower lung field. Laboratory studies show arterial hypoxemia and decreased PCO₂. A chest x-ray shows an area of opacification in the lower region of the right lung. Which of the following is the most likely cause of this patient's condition?
- (A) Alveolar proteinosis
 - (B) Aspiration
 - (C) Cigarette smoking
 - (D) Emphysema
 - (E) Vasculitis

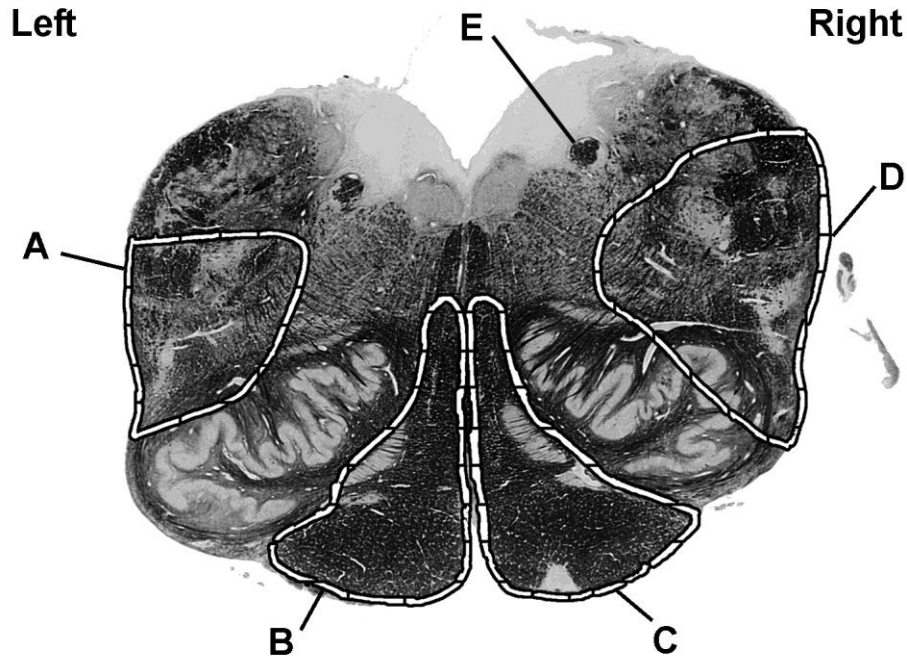
26. A 62-year-old man is admitted to the hospital for evaluation of abdominal pain. During the interview, he responds to the questions with a single word and sometimes with sarcastic answers. He does not engage in eye contact, and he frowns as he tells the physician that this is the third time he has been asked these questions. Which of the following is the most appropriate response by the physician?
- (A) "Can you tell me more about your abdominal pain?"
 - (B) "I understand that you do not feel well, but I need to get a history here."
 - (C) "I'll come back once you've calmed down, and we can talk more then."
 - (D) "Listen, if you choose not to cooperate, I'm not going to be able to help you."
 - (E) "You sound upset. Tell me a little more about that."
27. A 54-year-old man comes to the physician because of episodes of fainting for 3 months. He also has had difficulty performing daily tasks because he is easily fatigued. He had a myocardial infarction 12 years ago. His pulse is 40/min, respirations are 18/min, and blood pressure is 138/85 mm Hg. Physical examination shows evidence of cannon *a* waves. An ECG shows a P-wave rate of 90/min, and an R-wave rate of 40/min, with no apparent relation between the two. Which of the following is the most likely diagnosis?
- (A) First-degree atrioventricular block
 - (B) Right bundle branch block
 - (C) Second-degree atrioventricular block, type I
 - (D) Second-degree atrioventricular block, type II
 - (E) Third-degree atrioventricular block
28. A 42-year-old woman comes to the physician for a routine examination. She says that she has felt well except for occasional episodes of constipation, abdominal discomfort, and mild fatigue. She was treated for a renal calculus 10 years ago and was told she had a "lazy gallbladder." Her pulse is 82/min, and blood pressure is 150/80 mm Hg. Physical examination shows no other abnormalities. Laboratory studies show:

Erythrocyte count	3 million/mm ³
Serum	
K ⁺	4.5 mEq/L
Cl ⁻	107 mEq/L
Ca ²⁺	12 mg/dL
Phosphorus	2.2 mg/dL
Alkaline phosphatase	95 U/L

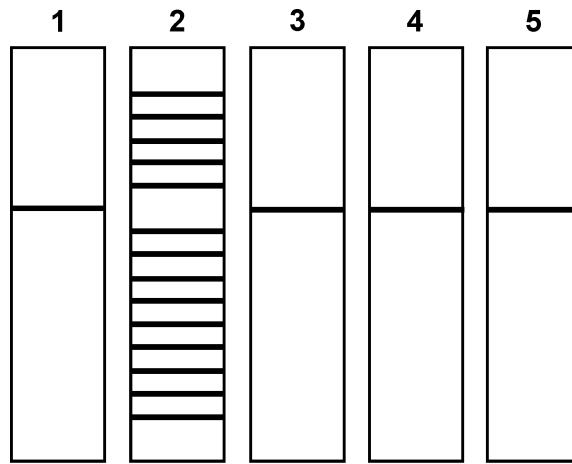
The most likely cause of this patient's condition is a small, well-defined nodule in which of the following locations?

- (A) Adrenal gland
- (B) Anterior pituitary gland
- (C) Gallbladder
- (D) Kidney
- (E) Parathyroid gland
- (F) Thymus

29. A 72-year-old woman is brought to the emergency department by her husband because of a 1-hour history of difficulty walking and speaking. The husband says that she was well last night but when she awoke this morning, she had difficulty getting out of bed and her speech was slurred. She has a 20-year history of type 2 diabetes mellitus well controlled with medication and diet. She is alert and oriented and is able to follow commands and respond verbally, but she has impaired speech. Her pulse is 80/min, respirations are 16/min, and blood pressure is 142/88 mm Hg. Physical examination shows left-sided hemiparesis. The tongue deviates to the right when protruded. Sensation to pinprick and temperature is normal, and proprioception and sensation to light touch are absent over the left upper and lower extremities. Which of the following labeled sites in the photograph of a cross section of a normal brain stem is most likely damaged in this patient?



30. A 68-year-old woman with end-stage renal disease comes to the office for a follow-up examination. She has required hemodialysis for the past year. Initially, she did well, but within the past 3 months, she has been admitted to the hospital for fluid overload because of poor adherence to fluid and salt restrictions. She says, "I'm so sick of being on dialysis. Following the restrictions is really hard." Which of the following is the most appropriate initial response by the physician?
- (A) "I imagine being on dialysis is frustrating, but you don't want to die from kidney disease, do you?"
 - (B) "I know that this is challenging, but do you remember how difficult it is to be hospitalized?"
 - (C) "It is tough to change your diet and fluid intake, but what sorts of things were you doing at first when you were following the recommendations?"
 - (D) "Making these changes is so difficult. Can you imagine how good you will feel once you make the changes again?"
 - (E) "This is very hard to do, but you may have an easier time if you met with the dietician again."



Lane 1: Liver
 Lane 2: Bone Marrow
 Lane 3: Kidney
 Lane 4: Cerebellum
 Lane 5: Pancreas

31. During an experiment, a Southern blot analysis is done by digesting DNA samples with a single restriction endonuclease, separating the digestion products by gel electrophoresis, and transferring them to a filter. The investigator probes the filter by exposing it to a cDNA clone that encodes a single immunoglobulin-constant region. The figure shows the resulting pattern with DNA samples isolated from different organs. Assuming there were no technical errors, the Southern blot analysis results demonstrate which of the following processes?
- (A) Affinity maturation
 - (B) Apoptosis
 - (C) Gene rearrangement
 - (D) RNA splicing
 - (E) Somatic hypermutation
-
32. A 17-year-old girl has never had a menstrual period. Physical examination shows a normal female body habitus, normal breast development, and normal appearing external genitalia. She has no axillary or pubic hair. The patient refuses to have a pelvic or rectal examination. Which of the following is the most likely explanation for the clinical presentation?
- (A) Androgen insensitivity
 - (B) Congenital adrenal hyperplasia
 - (C) Ectodermal dysplasia
 - (D) A psychiatric disorder
 - (E) A sex chromosome mosaicism

33. A 16-year-old boy is brought to the physician because of a 3-day history of abdominal pain and vomiting; he also has had decreased appetite during this period. The pain was initially on the right but now has become generalized. His temperature is 38.8°C (101.8°F), pulse is 100/min, respirations are 20/min, and blood pressure is 143/83 mm Hg. Abdominal examination shows guarding with diffuse rebound tenderness. There are no palpable masses. A CT scan of the abdomen shows a perforated appendix. Examination of peritoneal fluid from this patient will most likely show which of the following organisms?
- (A) *Candida albicans*
 - (B) *Citrobacter freundii*
 - (C) *Escherichia coli*
 - (D) *Staphylococcus aureus*
 - (E) *Streptococcus pneumoniae*
34. A 45-year-old woman comes to the office because of a 6-month history of hot flashes, night sweats, and insomnia. She has not had a menstrual period during this time. She thinks she is going through menopause and asks the physician if there are any medications that will alleviate her symptoms. Physical examination shows no abnormalities. The result of a urine pregnancy test is negative. The physician explains that hormone therapy likely will help and explains the risks to the patient. Which of the following is the next most appropriate physician statement?
- (A) "Could you tell me your thoughts about the hormone treatment option we have discussed?"
 - (B) "I have many patients with similar symptoms, and everyone responds to hormone therapy differently."
 - (C) "I will give you some written information to review, and then I can answer any remaining questions."
 - (D) "If your symptoms are really severe, the risk of hormone therapy may be worth it."
 - (E) "Would you like me to tell you what I think you should do?"
35. A randomized controlled trial is conducted to assess the risk for development of gastrointestinal adverse effects using azithromycin compared with erythromycin in the treatment of pertussis in children. Of the 100 children with pertussis enrolled, 50 receive azithromycin, and 50 receive erythromycin. Results show vomiting among 5 patients in the azithromycin group, compared with 15 patients in the erythromycin group. Which of the following best represents the absolute risk reduction for vomiting among patients in the azithromycin group?
- (A) 0.1
 - (B) 0.2
 - (C) 0.33
 - (D) 0.67
 - (E) 0.8

36. A 34-year-old woman with a 10-year history of hepatitis C comes to the physician because of progressive fatigue during the past month. Her vital signs are within normal limits. Physical examination shows that the liver is not palpable. Serum studies show:

Albumin	3 g/dL
Total bilirubin	1.8 mg/dL
Alkaline phosphatase	115 U/L
AST	53 U/L
ALT	48 U/L

A liver biopsy specimen shows focal areas of hepatocellular injury with infiltration of lymphocytes and early fibrosis. Which of the following mechanisms is the most likely cause of the ongoing hepatocyte injury in this patient?

- (A) Foreign peptides bound to class I MHC molecules are recognized by CD4+ T lymphocytes
 - (B) Foreign peptides bound to class I MHC molecules are recognized by CD8+ T lymphocytes
 - (C) Foreign peptides bound to class II MHC molecules are recognized by CD8+ T lymphocytes
 - (D) Self-peptides bound to class I MHC molecules are recognized by CD8+ T lymphocytes
 - (E) Self-peptides bound to class II MHC molecules are recognized by CD4+ T lymphocytes
-
37. A 50-year-old woman comes to the physician for a follow-up examination. Her blood pressure was 145/100 mm Hg and 145/95 mm Hg, respectively, at two previous visits. Today, her pulse is 75/min, respirations are 15/min, and blood pressure is 150/95 mm Hg. Physical examination shows no other abnormalities. If left untreated, which of the following is most likely to decrease in this patient?
- (A) Baroreceptor output
 - (B) Left ventricular stiffness during diastole
 - (C) Left ventricular stroke work
 - (D) Left ventricular wall thickness
 - (E) Myocardial oxygen consumption
38. A 62-year-old man comes to the physician for a follow-up examination after he was diagnosed with chronic inflammatory interstitial pneumonitis. Following pulmonary function testing, a biopsy specimen of the affected area of the lungs is obtained. Compared with a healthy man, analysis of this patient's biopsy specimen is most likely to show which of the following patterns of changes in the cell populations of alveoli?

	Type I Pneumocytes	Type II Pneumocytes	Fibroblasts
(A)	↑	↑	↑
(B)	↑	↑	↓
(C)	↑	↓	↑
(D)	↑	↓	↓
(E)	↓	↑	↑
(F)	↓	↑	↓
(G)	↓	↓	↑
(H)	↓	↓	↓

39. A 31-year-old woman with type 2 diabetes mellitus comes to the physician because of an oozing, foul-smelling wound on her foot for 2 days. Physical examination shows a 4-cm, necrotizing wound with a purplish black discoloration over the heel. Crepitant bullae producing profuse amounts of serous drainage are seen. A Gram stain of a tissue biopsy specimen shows gram-positive rods. The causal organism most likely produces which of the following virulence factors?
- (A) Endotoxin
 - (B) Fimbriae
 - (C) Pneumolysin
 - (D) Polysaccharide capsule
 - (E) α -Toxin
40. A 4-month-old boy with severe combined immunodeficiency receives a bone marrow transplant. Six days later, he develops a widespread, erythematous, maculopapular rash over the trunk. Examination of a skin biopsy specimen shows diffuse vacuolar degeneration of basal epidermal cells with a mononuclear inflammatory cell infiltrate. Which of the following is the most likely cause of this patient's rash?
- (A) Fixed drug eruption
 - (B) Graft-versus-host disease
 - (C) Immune complex deposition
 - (D) Mast cell degranulation
 - (E) Staphylococcal folliculitis

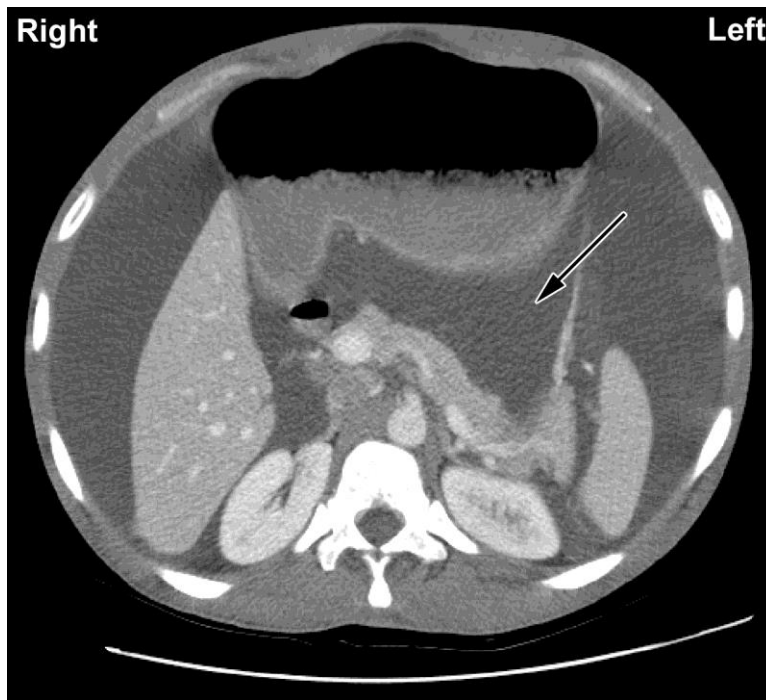
USMLE STEP 1 SAMPLE TEST QUESTIONS

BLOCK 2, ITEMS 41-80

41. A 37-year-old woman with right lower extremity edema is evaluated because of the sudden onset of shortness of breath and pleuritic chest pain. A diagnosis of pulmonary embolism is made. Which of the following signs, if present on physical examination, would be the most specific indicator of pulmonary arterial hypertension in this patient?
- (A) Increased jugular venous pressure
 - (B) P_2 louder than A_2
 - (C) Peripheral edema
 - (D) Presence of an S_3
 - (E) Pulmonary crackles
42. A 43-year-old woman with type 2 diabetes mellitus is brought to the emergency department because of a 12-hour history of nausea and vomiting. She says that it began after drinking champagne at a birthday party the previous night. Three days ago, she was diagnosed with *Trichomonas vaginalis* infection, and a 5-day course of metronidazole was initiated. Current medications also include acetaminophen, lisinopril, hydrochlorothiazide, and metformin. Her temperature is 37.2°C (99°F), pulse is 110/min, and blood pressure is 125/82 mm Hg. Physical examination shows pallor and dry mucous membranes. Which of the following is the most likely cause of this patient's nausea and vomiting?
- (A) Accumulation of acetaldehyde
 - (B) Gastritis secondary to alcohol
 - (C) Lactic acidosis secondary to metformin
 - (D) Metronidazole-induced hepatotoxicity
 - (E) Viral hepatitis
43. A 45-year-old man comes to the physician because of right shoulder pain that began after he chopped wood 2 days ago. Examination of the right upper extremity shows no obvious bone deformities or point tenderness. The pain is reproduced when the patient is asked to externally rotate the shoulder against resistance; there is no weakness. In addition to the teres minor, inflammation of which of the following tendons is most likely in this patient?
- (A) Infraspinatus
 - (B) Pectoralis
 - (C) Subscapularis
 - (D) Supraspinatus
 - (E) Trapezius
44. A 44-year-old man comes to the physician because of a 6-week history of progressive numbness of his feet. Two months ago, he completed a course of chemotherapy, including vincristine, for small cell lung carcinoma. Physical examination shows muscle weakness of the distal portion of the feet and absent ankle jerk reflexes. Sensation is decreased over the distal portions of the lower extremities. This patient's findings are most likely caused by which of the following mechanisms?
- (A) Apoptosis of dorsal root ganglion neurons
 - (B) Blockade of mitochondrial respiratory chain
 - (C) Decreased expression of myelin protein in Schwann cells
 - (D) Depolymerization of microtubules
 - (E) Inhibition of synaptic vesicle endocytosis

45. A 10-year-old girl is brought to the office by her mother because her school nurse thinks that she may have Marfan syndrome. She is at the 95th percentile for height and 25th percentile for weight. Physical examination shows a narrow palate with dental crowding, long slender extremities, and joint laxity. Molecular testing for *FBN1* shows a single nucleotide difference that does not change the amino acid at that locus. Her mother is 163 cm (5 ft 4 in) tall. There is no clinical evidence of Marfan syndrome in the mother, but she has the same single nucleotide change as the patient. The same nucleotide change is found in 15 of 200 individuals without Marfan syndrome. Which of the following best describes the single nucleotide change in the patient and her mother?
- (A) It is a disease-causing mutation in the patient and her mother
 - (B) It is a polymorphism
 - (C) It is a sequence variant of unknown significance
 - (D) It will change the folding of the protein
 - (E) It will result in a truncated protein
46. A 26-year-old woman comes to a busy emergency department because of a 2-day history of runny nose. She has no history of major medical illness and takes no medications. Her vital signs are within normal limits. The patient has to wait 6 hours before she is seen by a physician. She is angry with the staff and says the only reason she had to wait this long is because she does not have insurance. In addition to apologizing to the patient, which of the following is the most appropriate opening remark by the physician?
- (A) "It is harsh to suggest that you waited because you don't have insurance, but how can we help you feel better today?"
 - (B) "It sounds like you are angry; shall I come back in a few minutes?"
 - (C) "Our wait time has nothing to do with insurance, so let's talk about the reason you are here."
 - (D) "The reason you waited so long is because we need to triage by severity."
 - (E) "Thank you for waiting. How can I help you today?"
47. A 26-year-old man is brought to the emergency department by ambulance 30 minutes after being shot in the leg. He is unconscious and appears markedly pale. His pulse is 120/min, respirations are 16/min, and blood pressure is 80/60 mm Hg. Compared with a healthy adult, which of the following findings is most likely in this patient?

	Arterial Baroreceptor Firing Rate	Systemic Vascular Resistance	Pulmonary Vascular Resistance	Systemic Capillary Fluid Transfer
(A)	↑	↑	↑	filtration
(B)	↑	↓	↑	absorption
(C)	↑	↓	↓	filtration
(D)	↓	↑	↑	absorption
(E)	↓	↑	↓	filtration
(F)	↓	↓	↓	absorption



48. A 36-year-old man with profound intellectual disability is brought to the physician by staff at his facility because of increasing abdominal girth during the past 2 weeks. He is unable to speak, and no medical history is currently available. Physical examination shows a protuberant abdomen with a fluid wave and shifting dullness. There are no signs of trauma to the area. Laboratory studies show no abnormalities. A CT scan of the abdomen is shown. Fluid is present in which of the following areas as indicated by the arrow?
- (A) Epiploic foramen
 - (B) Gastrosplenic ligament
 - (C) Hepatorenal pouch (of Morison)
 - (D) Omental bursa (lesser sac)
 - (E) Sulcus pericolicus

49. A new test has been developed to detect the presence of a tumor-specific protein in serum. The initial evaluation of this test shows:

		Tumor		
		Present	Absent	
Test Result	Positive	40	20	60
	Negative	10	30	40
		50	50	100

Which of the following is the likelihood that a patient with a positive test from this sample has a tumor?

- (A) 0.25
- (B) 0.33
- (C) 0.67
- (D) 0.75
- (E) 0.80

50. A 75-year-old woman with type 2 diabetes mellitus and hypertension is brought to the office by her daughter because of a 4-month history of loss of appetite. The patient has had a 6.8-kg (15-lb) weight loss during this time. She immigrated to the USA from Argentina 35 years ago. She is fluent in Spanish and has limited English language proficiency. The patient's daughter is bilingual. The physician studied Spanish in high school. The clinic receptionist is bilingual. A certified interpreter is not available at the clinic, but a telephone interpreter service is available. Which of the following is the most appropriate person to serve as an interpreter for this patient encounter?
- (A) Bilingual staff member
 - (B) Patient's daughter
 - (C) Physician
 - (D) Telephone interpreter
51. During a study of renal glomeruli, a healthy animal kidney is kept in a vascular bath preparation at a constant afferent arterial pressure of 100 mm Hg. If the efferent arteriole is constricted with a vascular clamp, which of the following Starling forces is most likely to change in the glomeruli?
- (A) Decreased filtration coefficient (K_f)
 - (B) Decreased hydrostatic pressure
 - (C) Decreased oncotic pressure
 - (D) Increased hydrostatic pressure
 - (E) Increased oncotic pressure
52. A 2-year-old boy is brought to the physician for a well-child examination. He was delivered at term after an uncomplicated pregnancy. His birth weight was 3500 g (7 lb 11 oz), and Apgar scores were 8 and 10 at 1 and 5 minutes, respectively. At the age of 15 months, physical examination showed no abnormalities, but he was not yet talking. Both of his parents had learning difficulties in school, and his mother stopped attending after the 10th grade. He has a maternal uncle with cognitive disabilities. He is at the 25th percentile for height, 15th percentile for weight, and 90th percentile for head circumference. He appears irritable, he resists making eye contact, and he is flapping his hands. Which of the following is the most likely cause of this patient's condition?
- (A) Creation of an alternative splice site
 - (B) Frameshift mutation
 - (C) Missense mutation
 - (D) Nonsense mutation
 - (E) Trinucleotide repeat expansion
53. A 55-year-old woman is diagnosed with parathyroid adenoma after ultrasonography of the neck showed a soft-tissue, hypoechoic mass at the back of the left lobe of the thyroid bed. Surgical removal of the mass is planned, and the patient is admitted to the hospital. During this procedure, ligation of which of the following vessels is most appropriate to ensure hemostasis in this patient?
- (A) Ascending pharyngeal artery
 - (B) Costocervical trunk
 - (C) Inferior thyroid artery
 - (D) Internal thoracic artery
 - (E) Transverse cervical artery

54. A 46-year-old woman comes to the physician because of a 2-month history of fatigue and muscle weakness. She has a 10-year history of hypertension treated with a thiazide diuretic. She drinks five 12-oz beers each evening and sometimes more on weekends. Her pulse is 90/min, and blood pressure is 105/60 mm Hg while seated; pulse is 95/min, and blood pressure is 99/59 mm Hg while standing. Physical examination shows brisk reflexes. Laboratory studies show:

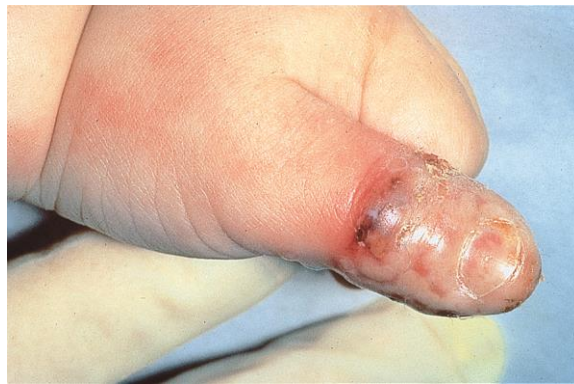Hemoglobin	12 g/dL
Hematocrit	35%
Serum	
K ⁺	3.3 mEq/L
Glucose	110 mg/dL

Which of the following is the most likely cause of these findings?

- (A) Adverse drug effect
 - (B) Alcohol intoxication
 - (C) Dehydration
 - (D) Iron deficiency anemia
 - (E) Orthostatic hypotension
-
55. A 55-year-old man who is a business executive is admitted to the hospital for evaluation of abdominal pain. He is polite to the physician but berates the nurses and other staff. The patient's wife and two of his three adult children arrive for a visit. The patient says with disgust that the missing child is and always has been worthless. Which of the following is the most likely explanation for this patient's behavior?
- (A) Countertransference
 - (B) Projection
 - (C) Projective identification
 - (D) Reaction formation
 - (E) Splitting
56. A study is designed to evaluate the feasibility of acupuncture in children with chronic headaches. Sixty children with chronic headaches are recruited for the study. In addition to their usual therapy, all children are treated with acupuncture three times a week for 2 months. Which of the following best describes this study design?
- (A) Case-control
 - (B) Case series
 - (C) Crossover
 - (D) Cross-sectional
 - (E) Historical cohort
 - (F) Randomized clinical trial

57. A 6-year-old girl is admitted to the hospital because of a 1-week history of constant increasingly severe neck pain and a 2-month history of severe headaches that occur three to four times weekly and last for 1 hour. She also has had four episodes of otitis media and three urinary tract infections during the past 4 years. Today, her temperature is 37.6°C (99.6°F), pulse is 78/min, respirations are 20/min, and blood pressure is 95/63 mm Hg. Examination of the neck shows no palpable masses, but there is generalized hyperreflexia and Babinski sign is present. CT scan of the mastoid area shows bone destruction in the right mastoid and right internal ear. Examination of a biopsy specimen of the retropharyngeal area shows aggregates of segmented neutrophils as well as evidence of *Candida albicans*. Immunologic studies show a neutrophil count of 9800/ μ L, but these cells show a delay in bactericidal activity against *Staphylococcus aureus*. The most likely cause of this patient's condition is a homozygous mutation in which of the following genes?

- (A) Catalase
- (B) Lactate dehydrogenase
- (C) Myeloperoxidase
- (D) Nitric oxide synthase
- (E) Superoxide dismutase



58. A 2-year-old boy is brought to the office by his mother because of a 1-day history of severe pain, swelling, and redness of his left thumb. The mother does not recall any trauma to the area. She says he has been eating poorly during this period, but otherwise he has been behaving normally. He has no history of major medical illness and receives no medications. He appears tearful. He is at the 90th percentile for length and 80th percentile for weight. His temperature is 37.7°C (99.8°F), pulse is 100/min, respirations are 20/min, and blood pressure is 100/50 mm Hg. Physical examination shows an oral vesicle, cervical lymphadenopathy, and the findings in the photograph. Which of the following types of infectious agents is the most likely cause of the findings in this patient's finger?

- (A) DNA virus
- (B) Gram-negative bacterium
- (C) Gram-positive bacterium
- (D) RNA virus
- (E) Yeast

59. A 7-year-old boy who lives in Kentucky is brought to the office by his mother because of a 2-week history of cramping abdominal pain and diarrhea. Three hours ago, the patient thought he had accidentally defecated in his pants. The mother says that she looked in his underpants and saw something move, which she captured. She says that it looked like an earthworm. The patient has had no fever, cough, or blood-tinged sputum. He has not traveled recently. Physical examination, including rectal examination, shows no abnormalities. This patient most likely acquired the causal infectious agent via which of the following modes of transmission?
- (A) Black fly bite
 - (B) Contact with infected puppies
 - (C) Ingestion of soil
 - (D) Mosquito bite
 - (E) Tick bite
60. A sexually active 23-year-old man with multiple sex partners has dysuria and a yellow urethral exudate. Gram stain of the exudate shows numerous neutrophils, many that contain intracellular gram-negative diplococci. He has had three similar episodes of urethritis over the past 2 years. Which of the following properties of the infecting organism best explains the reinfection?
- (A) Antigenic variation
 - (B) Catalase
 - (C) Inhibition of B-lymphocyte function
 - (D) Inhibition of T-lymphocyte function
 - (E) Polysaccharide capsule
61. A 23-year-old woman comes to the physician for genetic counseling prior to conception. Her brother and maternal uncle had Duchenne muscular dystrophy (DMD) and died at the ages of 28 and 17 years, respectively. Genetic analysis was not performed on either relative prior to death. Serum studies show a muscle creatine kinase concentration of 120 U/L (N=22–198). The patient's 50-year-old mother has a serum muscle creatine kinase concentration of 300 U/L. Which of the following is the most appropriate assessment of this patient's carrier status for this disease?
- (A) The patient has a 50% risk for developing DMD
 - (B) The patient has a 50% risk of having a child with DMD
 - (C) The patient is a carrier of the disease based on her family history of DMD
 - (D) The patient is not a carrier of the DMD based on her normal creatine kinase concentration
 - (E) The patient's DMD carrier status is uncertain because of random X inactivation

62. A 20-year-old woman comes to the physician because of a 5-year history of heavy bleeding with menses that often requires her to change her sanitary pads three times hourly. Menses occur at regular 28-day intervals. She recently sustained a minor cut to her finger, and the bleeding took longer to stop than usual. She has not had easy bruising or change in weight. She only takes an oral contraceptive, but she has not been sexually active for the past 6 months. Her temperature is 37.5°C (99.5°F), pulse is 72/min, respirations are 12/min, and blood pressure is 120/66 mm Hg. Physical examination shows mildly pale conjunctivae. Pelvic examination shows no abnormalities. Laboratory studies show:

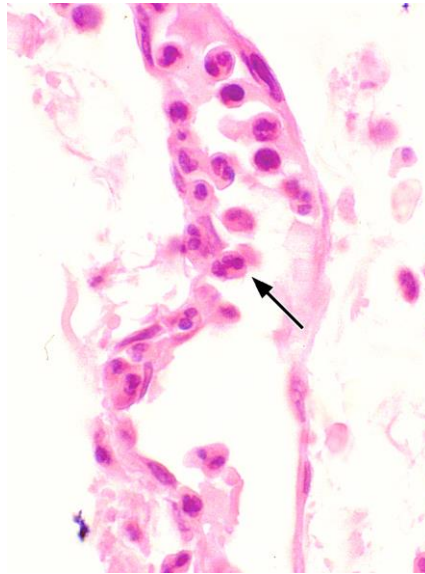
Hemoglobin	10.5 g/dL
Hematocrit	31.3%
Mean corpuscular hemoglobin concentration	28% Hb/cell
Mean corpuscular volume	70 μm^3
Leukocyte count	5500/mm ³
Platelet count	275,000/mm ³
Platelet aggregation studies	normal
Prothrombin time	10.5 sec (INR=1.0)
Partial thromboplastin time	28 sec

A Pap smear shows no abnormalities. Which of the following hematologic disorders is the most likely cause of this patient's menorrhagia?

- (A) Afibrinogenemia
- (B) Hemophilia A
- (C) Intravascular coagulation
- (D) Vitamin K deficiency
- (E) von Willebrand disease

-
63. A 32-year-old man is brought to the emergency department 30 minutes after being struck by a car while driving his motorcycle. He reports severe pelvic pain. On examination, there is bruising of the perineum and pain is elicited with motion of his pelvis. Blood is noted at the urethral meatus. There is no other penile trauma. A plain x-ray shows a fracture of the superior pubic ramus and retrograde urethrography is done to evaluate for a urethral disruption. Which of the following portions of the urethra would be at greatest risk for injury in this patient?

- (A) Intramural (pre-prostatic)
- (B) Membranous
- (C) Prostatic
- (D) Spongy



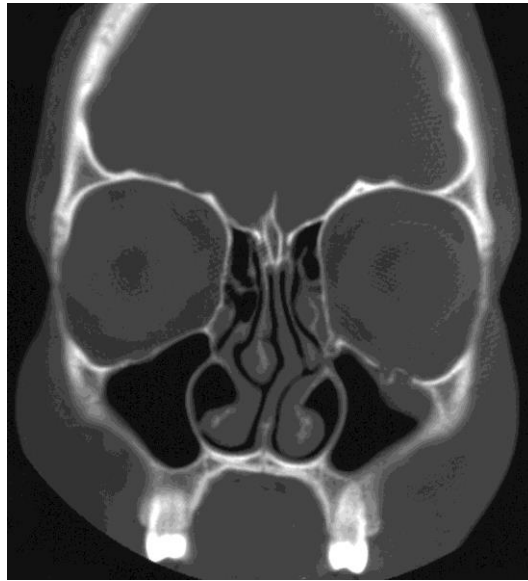
64. A 63-year-old man is brought to the emergency department 1 hour after police found him unresponsive. His respirations are 30/min. Crackles are heard over the left upper and the entire right lung fields. Despite appropriate lifesaving measures, he dies. A photomicrograph of a section of the right lung obtained at autopsy is shown. Which of the following mediators is the most likely cause of the position of the cell indicated by the arrow?
- (A) Bradykinin
 - (B) C5a
 - (C) Histamine
 - (D) Nitrous oxide
 - (E) Prostaglandins
-
65. A 25-year-old woman comes to the office because of a 6-month history of increasingly severe low back pain and heavy menses. Her temperature is 37.1°C (98.8°F), pulse is 75/min, respirations are 13/min, and blood pressure is 115/79 mm Hg. Physical examination shows no abnormalities. An endometrial biopsy specimen shows regular tubular endometrial glands with abundant mitotic figures in the endometrial glands and stroma. Which of the following proteins or enzymes regulate the progression of cells into this phase of this patient's menstrual cycle?
- (A) AMP-dependent kinases
 - (B) Cyclin-dependent kinases
 - (C) Hexokinases
 - (D) Lipid kinases
 - (E) Urokinases
66. A 29-year-old woman is prescribed carbamazepine for trigeminal neuralgia. She has a strong family history of osteoporosis. As a result, the physician also advises her to increase her intake of vitamin D. The most likely reason for this recommendation is that carbamazepine may affect which of the following pharmacokinetic processes?
- (A) Absorption
 - (B) Distribution
 - (C) Excretion
 - (D) Metabolism
 - (E) Protein binding

67. An 18-year-old woman is brought to the emergency department because of a 1-day history of fever, dizziness, weakness, rash, nausea, and vomiting. She has been using synthetic sanitary pads and tampons since her last menstrual period began 2 days ago. She has a history of recurrent urinary tract infections treated with trimethoprim-sulfamethoxazole. Current medications also include aspirin and an herbal supplement for menstrual cramps as needed. Her temperature is 39°C (102.2°F), pulse is 100/min, and blood pressure is 85/55 mm Hg. Physical examination shows injected conjunctivae and a fine, erythematous rash over the trunk, palms, and soles of the feet. Oral and pelvic examinations show erythema of the mucous membranes. Laboratory studies show:

Leukocyte count	15,000/mm ³
Segmented neutrophils	75%
Bands	5%
Eosinophils	1%
Lymphocytes	15%
Monocytes	4%
Platelet count	100,000/mm ³
Serum	
AST	100 U/L
ALT	80 U/L

The patient's use of which of the following most likely increased her risk for this condition?

- (A) Aspirin
 - (B) Herbal supplement
 - (C) Sanitary pads
 - (D) Tampons
 - (E) Trimethoprim-sulfamethoxazole
-
68. A 53-year-old man comes to the physician because of a 6-month history of intermittent blood in his stool. He has had no pain with defecation. Physical examination shows a 1-cm, visible anal mass located below the dentate line. A biopsy of the mass is scheduled. If the mass is found to be malignant, it is most appropriate to evaluate which of the following lymph nodes for possible metastasis?
- (A) Internal iliac
 - (B) Popliteal
 - (C) Sacral
 - (D) Superficial inguinal
 - (E) Superior rectal
69. A 14-year-old boy is brought to the physician for a physical examination prior to participating in sports. He appears reluctant to remove his shirt for the examination, and says that he is embarrassed because he has grown breasts during the past year. He is at the 50th percentile for height and weight. Physical examination shows bilateral 1.5-cm fibroglandular masses located beneath the nipple-areolar complex and normal penis and testes. Pubic hair development is Tanner stage 3. Serum concentrations of gonadotropic hormones, estrogens, and testosterone are within the reference ranges. Which of the following is the most likely cause of this patient's breast enlargement?
- (A) Breast adenocarcinoma
 - (B) Estradiol-secreting Leydig cell tumor
 - (C) Peutz-Jeghers syndrome
 - (D) Seminiferous tubule dysgenesis (Klinefelter syndrome)
 - (E) Normal development



70. A 24-year-old man is brought to the emergency department by paramedics 30 minutes after he was involved in a motor vehicle collision in which his face struck the steering wheel. He was the unrestrained driver. On arrival, he has moderate facial pain and double vision on upward gaze. He has no history of serious illness and takes no medications. Vital signs are within normal limits. Examination of the left eye shows periorbital ecchymoses and infraorbital edema. Ocular movement is restricted vertically. Examination of the right eye shows no abnormalities. Visual acuity is 20/20 bilaterally. CT scan of the orbits is shown. The remainder of the examination is most likely to disclose impairment of which of the following on this patient's left side?
- (A) Hearing
 - (B) Lacrimation
 - (C) Pupillary reflex
 - (D) Saliva production
 - (E) Sensation over the upper lip
-
71. A 23-year-old woman is brought to the medical tent 2 minutes after she collapsed at the finish line of a marathon. She has not lost consciousness; she is alert and coherent and says she feels dizzy and light-headed. She does not have headache or nausea. She has no history of major medical illness and takes no medications. Her pulse is 120/min, and blood pressure is 85/50 mm Hg; other vital signs are within normal limits. Physical examination shows no other abnormalities. She is placed on a cot, her feet are elevated, and an infusion of 0.9% saline is begun. Thirty minutes later, her pulse is 70/min, and blood pressure is 110/70 mm Hg. She says she feels well and begins eating orange slices. Which of the following best describes this patient's condition?
- (A) Autonomic dysfunction
 - (B) Hypokalemia
 - (C) Hyponatremia
 - (D) Myocardial inflammation
 - (E) Orthostatic hypotension

72. A 27-year-old man comes to the emergency department because of a 3-hour history of pain around his navel. He also has had nausea and one episode of vomiting 1 hour ago. During the past year, he has had multiple episodes of dark stools, which last for 2 to 3 days and resolve spontaneously. He underwent an appendectomy 2 years ago. The patient says that his current symptoms are similar to those he had during the appendicitis episode. His temperature is 39.0°C (102.2°F), pulse is 94/min, respirations are 22/min, and blood pressure is 114/78 mm Hg. Pulse oximetry on room air shows an oxygen saturation of 99%. Physical examination shows rebound tenderness localized over the right lower quadrant. Results of laboratory studies are shown:

Hemoglobin	12 g/dL
Hematocrit	36%
Leukocyte count	18,000/mm ³
Platelet count	350,000/mm ³
Serum	
Urea nitrogen	20 mg/dL
Creatinine	0.7 mg/dL

CT scan of the abdomen shows fat stranding in the mesentery of the small bowel with an area of inflammation in a segment of the small bowel. Urgent laparotomy shows a segment of inflamed small bowel in the terminal ileum; there is a 2 x 2-cm bulge in the antimesenteric border of the inflamed segment. Histologic examination of a biopsy specimen of this bulging area is most likely to show which of the following in this patient?

- (A) Choristoma
- (B) Ciliary epithelium
- (C) Endothelial cells
- (D) Gastric mucosa
- (E) Striated muscle

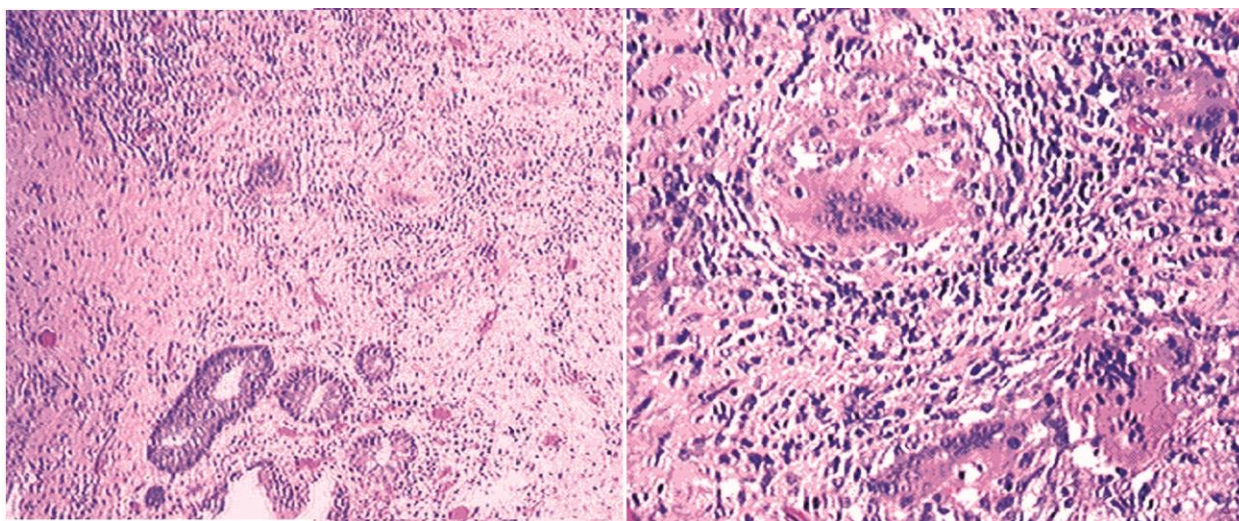
-
73. A 14-year-old girl is brought to the physician after her mother learned that she began having sexual intercourse with various partners 1 month ago. She does not use condoms or other contraception. The mother is concerned about her behavior. The patient's parents separated 3 months ago. She had been an honor student and excelled in sports and leadership positions at school before the separation. Since the separation, however, she has become sullen, defiant, and rebellious. She has begun smoking cigarettes, disobeying her curfew, and being truant from school. This patient is most likely using which of the following defense mechanisms?

- (A) Acting out
- (B) Displacement
- (C) Projection
- (D) Reaction formation
- (E) Sublimation

74. A 38-year-old woman, gravida 3, para 2, at approximately 36 weeks' gestation, comes to the emergency department because of a 4-hour history of contractions. She has received no prenatal care but reports two uncomplicated vaginal deliveries 5 and 8 years ago. She is in mild distress because of pain that she rates as a 7 on a 10-point scale. Abdominal examination is consistent with a uterus at full term. Ultrasonography shows oligohydramnios and a full-term fetus with a large left kidney and an empty right renal fossa. It is most appropriate to obtain specific additional history regarding maternal use of which of the following during pregnancy?

- (A) ACE inhibitors
- (B) Antiepileptic drugs
- (C) Marijuana
- (D) Oral contraceptives
- (E) Stimulants

75. A 65-year-old woman with asthma is brought to the emergency department because of shortness of breath and light-headedness since taking her first dose of aspirin 30 minutes ago for primary prevention of coronary artery disease. She had a similar reaction 5 years ago after taking ibuprofen. Her pulse is 120/min, respirations are 25/min, and blood pressure is 90/60 mm Hg. Bilateral wheezing is heard over all lung fields. The most likely underlying cause of this patient's condition is accumulation of which of the following mediators?
- (A) Endoperoxides
 - (B) Leukotrienes
 - (C) Prostacyclin (PGI₂)
 - (D) Prostaglandins
 - (E) Thromboxane
76. A 19-year-old man with asthma comes to a new physician for an initial examination. He has been treated in the emergency department multiple times during the past 7 months because of acute exacerbations of asthma. The patient says that he has received care only from emergency department physicians on an almost monthly basis during the past 4 years, and he has managed his symptoms with inhaled β_2 -adrenergic agonists. The patient says, "All the doctors I've seen just don't understand me. They keep prescribing inhalers that don't work, including that steroid inhaler they gave me recently." He has no other history of major medical illness. He does not appear to be in respiratory distress. Mild end-expiratory wheezing is heard over all lung fields. Which of the following is the most appropriate statement by the physician at this time?
- (A) "Are you sure that you're taking your medications appropriately?"
 - (B) "I'm confident that I can help you with your asthma. I will order pulmonary function tests to see exactly what the problem is."
 - (C) "Tell me what you know about the steroid inhalers and how they are supposed to work."
 - (D) "Your asthma seems particularly difficult to control. I'd like to refer you to an asthma specialist."
 - (E) "You're probably allergic to something at your home, so we'll need to figure out what that is before your asthma can get better."
77. A healthy 22-year-old man participates in a study of glucose metabolism. At the beginning of the study, his serum glucose concentration is within the reference range. He consumes an 800-calorie meal consisting of protein, fat, and carbohydrates. He then sleeps through the night without additional food or drink. Twelve hours later, his serum glucose concentration remains within the reference range. Which of the following mechanisms is most likely involved in maintaining this man's serum glucose concentration?
- (A) Continued gut absorption of calories from the ingested meal
 - (B) Glucose release from skeletal muscle
 - (C) Glycogenolysis in the liver
 - (D) Increased leptin release from adipose tissues
 - (E) Inhibition of glucagon release by the pancreas



78. A 30-year-old man is admitted to the hospital for evaluation. He has a 6-week history of colicky abdominal pain and diarrhea with occasional blood. Three days after admission, he suddenly develops peritonitis and sepsis. Despite appropriate care, he dies. At autopsy, examination shows a fibrinous exudate over the peritoneal and serosal surfaces, and a punctate opening is seen in the wall of a thickened loop of small intestine. Several lengths of the small and large intestines are also thickened and adherent to one another, with marked areas of narrowing. Photomicrographs of a section of the colon are shown. Which of the following is the most likely diagnosis?
- (A) Colon cancer
 - (B) Crohn disease
 - (C) Diverticulitis
 - (D) Ischemic necrosis
 - (E) Ulcerative colitis
-
79. A 3-month-old boy is brought to the emergency department because of a 2-hour history of respiratory distress. His pulse is 120/min, respirations are 40/min, and blood pressure is 80/50 mm Hg. Pulse oximetry on room air shows an oxygen saturation of 82%. Physical examination shows cyanosis. Cardiac examination shows no murmur. A chest x-ray shows no abnormalities. A blood sample appears brown. The most likely cause of this patient's condition is which of the following abnormalities?
- (A) Decreased activity in the enzyme that reduces Fe^{3+} to Fe^{2+}
 - (B) Decreased erythrocyte production
 - (C) Inability of the porphyrin ring to stay attached to hemoglobin
 - (D) Increased iron in the body
 - (E) Mutation of one of the codons for hemoglobin
80. A 68-year-old woman comes to the emergency department because of a 1-day history of fever and pain and swelling of her left leg. She has a history of chronic lower extremity edema. Physical examination shows dry, scaly skin over the lower extremities, and a swollen, erythematous, hot, and tender left calf. One day later, blood cultures grow gram-positive, catalase-negative cocci that exhibit clear zones of hemolysis on blood agar plates. There is no growth when bacitracin is added to the plate. Which of the following species of *Streptococcus* is the most likely causal organism?
- (A) *S. agalactiae* (group B)
 - (B) *S. mitis*
 - (C) *S. pneumoniae*
 - (D) *S. pyogenes* (group A)
 - (E) Viridans streptococcus

USMLE STEP 1 SAMPLE TEST QUESTIONS

BLOCK 3, ITEMS 81-119

81. A 62-year-old woman comes to the physician because of low back pain for 1 week. Menopause occurred 10 years ago. Physical examination shows localized tenderness over the lumbar spine after movement. X-rays of the spine show a compression fracture of L1-2. A DEXA scan shows decreased bone mineral density. Serum calcium and phosphorus concentrations and serum alkaline phosphatase activity are within the reference ranges. A bisphosphonate drug is prescribed. The expected beneficial effect of this drug is most likely due to which of the following actions?
- (A) Decreased insulin-like growth factor-1 concentration
 - (B) Decreased osteoclast activity
 - (C) Decreased osteoprotegerin production
 - (D) Increased 1,25-dihydroxycholecalciferol concentration
 - (E) Increased osteoblast activity
 - (F) Increased receptor activator of NF- κ B ligand (RANKL) production
82. In a cohort study of elderly women, the relative risk ratio for hip fractures among those who exercise regularly is 1.2 (95% confidence interval of 1.1 to 1.8). Which of the following is the most appropriate conclusion about the effect of regular exercise on the risk for hip fracture?
- (A) Statistically nonsignificant increase in risk
 - (B) Statistically nonsignificant overall decrease in risk
 - (C) Statistically significant overall decrease in risk
 - (D) Statistically significant overall increase in risk
83. A 52-year-old man is brought to the emergency department 30 minutes after he had an episode of chest pain radiating to his jaw while shoveling snow. His pulse is 80/min, and blood pressure is 130/70 mm Hg. The lungs are clear to auscultation. Cardiac examination shows an S₄. While undergoing an ECG, the patient says that he feels the chest pain returning. The most appropriate immediate treatment is a drug with which of the following mechanisms of action?
- (A) Increases cAMP concentration
 - (B) Increases nitric oxide concentration
 - (C) Inhibits potassium flux
 - (D) Inhibits sodium flux
84. A 24-year-old woman comes to the physician for a follow-up examination. One week ago, she was treated in the emergency department after she accidentally spilled hot grease on her left leg while working at a fast-food restaurant. Examination of the left lower extremity shows a 7-cm, pink, soft, granular, edematous wound. The formation of this tissue was most likely caused by increased activity of which of the following?
- (A) Complement C3b
 - (B) Glycosylation-dependent cell adhesion molecule-1
 - (C) P-selectin
 - (D) Stromelysin
 - (E) Vascular endothelial growth factor

85. A 27-year-old man is admitted to the hospital 45 minutes after being involved in a motor vehicle collision. Physical examination shows a sluggish response to stimuli. Neurologic examination shows no other abnormalities. A skull x-ray shows a linear, nondepressed basal skull fracture. Two weeks later, the patient develops polyuria and polydipsia. Laboratory studies show a serum glucose concentration within the reference range, increased serum osmolality, and decreased urine osmolality. Following the administration of desmopressin, urine osmolality increases. The beneficial effect of this drug is most likely due to activation of which of the following?
- (A) Adenylyl cyclase
 - (B) Ca^{2+} channels
 - (C) Janus kinase
 - (D) Serine kinase
 - (E) Tyrosine kinase
86. A 10-month-old boy is brought to the physician because of a 4-day history of fever and cough. His illness began with low-grade fever and copious, clear nasal discharge. Two days ago he developed a moist, nonproductive cough and rapid breathing. He has received all scheduled childhood immunizations. He attends a large day-care center and has three school-aged siblings. His temperature is 38°C (100.4°F), pulse is 101/min, respirations are 38/min, and blood pressure is 85/60 mm Hg. Physical examination shows nasal flaring and rhinorrhea. Chest examination shows intercostal retractions along with bilateral, diffuse wheezes and expiratory rhonchi. The infectious agent of this patient's condition most likely has which of the following properties?
- (A) DNA genome
 - (B) Double-stranded nucleic acid genome
 - (C) Mature virion lacking viral polymerase
 - (D) Mediation of cell entry via a fusion protein
 - (E) Viability on surfaces for several weeks
87. A 17-year-old girl is brought to the emergency department 15 minutes after being stung by a bee. She has mild light-headedness but no difficulty swallowing. Her temperature is 37.1°C (98.8°F), pulse is 100/min, respirations are 30/min, and blood pressure is 115/70 mm Hg. Physical examination shows no urticaria. Bilateral wheezing is heard on auscultation of the chest. Which of the following types of drugs is the most appropriate pharmacotherapy for this patient?
- (A) α_1 -Adrenergic agonist
 - (B) α_2 -Adrenergic agonist
 - (C) α_1 -Adrenergic antagonist
 - (D) β_2 -Adrenergic agonist
 - (E) β_2 -Adrenergic antagonist
88. A 14-year-old boy is brought to the physician because of a 2-day history of a sore throat and fever that peaks in the late afternoon. He also has a 1-week history of progressive fatigue. He recently began having unprotected sexual intercourse with one partner. He appears ill. His temperature is 39°C (102.2°F). Physical examination shows cervical lymphadenopathy and pharyngeal erythema with a creamy exudate. Which of the following is the most likely diagnosis?
- (A) Candidiasis
 - (B) Herpangina
 - (C) Infectious mononucleosis
 - (D) Mumps
 - (E) Syphilis

89. A 57-year-old man receives radiation therapy for a squamous cell carcinoma of the lung. Despite therapy, the tumor progressively increases in size, and he dies 6 months later. His tumor cells contain a point mutation in the p53 gene (*TP53*), leading to an inactive gene product. Based on this finding, the progressive tumor growth despite irradiation therapy is most likely to be related to a defect in cell cycle arrest in which of the following phases of the cell cycle?

(A) G₀
(B) G₁
(C) G₂
(D) M
(E) S

90. A 28-year-old man comes to the physician because of a 1-year history of pain with urination that has increased in severity during the past month. He also has had episodes of blood in his urine during the past 5 years. He lived in sub-Saharan Africa until he came to the USA 6 months ago for graduate school. His temperature is 38°C (100.4°F), pulse is 80/min, respirations are 16/min, and blood pressure is 110/84 mm Hg. Physical examination shows suprapubic tenderness. Laboratory studies show:

Hemoglobin	12.3 g/dL
Hematocrit	37%
Leukocyte count	13,400/mm ³
Segmented neutrophils	65%
Bands	5%
Eosinophils	5%
Lymphocytes	22%
Monocytes	3%
Serum	
Urea nitrogen	75 mg/dL
Creatinine	3.8 mg/dL
Urine	
Blood	3+
RBC	200/hpf
WBC	100/hpf
RBC casts	absent
WBC casts	absent

Imaging studies show bilateral hydroureter and hydronephrosis and foci of calcification in the region of the bladder. A biopsy specimen of the bladder shows marked chronic inflammation with fibrosis and scattered granulomas. Which of the following best explains the biopsy findings?

(A) Exposure to a chemical toxin
(B) Interstitial cystitis
(C) Malacoplakia
(D) Schistosomiasis
(E) Vesicoureteral reflux

91. A couple comes for preconceptional genetic counseling because they both have a family history of α -thalassemia. The woman has a minimally decreased hemoglobin concentration. Genetic studies show a single gene deletion. The man has microcytic anemia and a two-gene deletion. If the two-gene deletion is in *trans* (one deletion on the maternal gene and one deletion on the paternal gene), which of the following percentages of their offspring will have a two-gene deletion?

(A) 0%
(B) 25%
(C) 50%
(D) 75%
(E) 100%

92. A previously healthy 40-year-old woman is brought to the emergency department by her husband because of a 2-day history of fever, lethargy, and confusion. Her temperature is 38°C (100.4°F), pulse is 80/min, respirations are 18/min, and blood pressure is 140/90 mm Hg. Physical examination shows scattered petechiae and ecchymoses over the lower extremities. Neurologic examination shows moderate generalized motor weakness. She is oriented to person but not to place or time. Laboratory studies show:

Hemoglobin	9 g/dL
Hematocrit	27%
Leukocyte count	8000/mm ³ with a normal differential
Platelet count	15,000/mm ³
Prothrombin time	12 sec (INR=1.1)
Partial thromboplastin time	30 sec
Serum	
Urea nitrogen	25 mg/dL
Lactate dehydrogenase	1000 U/L

A peripheral blood smear shows 3+ polychromasia and 3+ schistocytes. Urine and blood cultures grow no organisms. A chest x-ray shows no abnormalities. Which of the following is the most likely diagnosis?

(A) Acute myeloid leukemia
(B) Autoimmune hemolytic anemia
(C) Thrombotic thrombocytopenic purpura
(D) Toxic shock syndrome
(E) von Willebrand disease

-
93. A 16-year-old boy is admitted to the emergency department because of a knife wound to the left side of his chest. An x-ray of the chest shows an air-fluid level in the left side of the chest, partial collapse of the left lung, and elevation of the stomach bubble. The mediastinum is in the midline. Which of the following is the most likely diagnosis?

(A) Hemopneumothorax, not under tension
(B) Hemothorax, not under tension
(C) Pneumothorax, not under tension
(D) Tension hemopneumothorax
(E) Tension hemothorax
(F) Tension pneumothorax

94. A 49-year-old woman comes to the physician for a follow-up examination. She has a strong family history of coronary artery disease. Her blood pressure has ranged from 150/95 mm Hg to 130/85 mm Hg during the previous three visits within the past 2 months. Her blood pressure today is 140/90 mm Hg. Physical examination shows no other abnormalities. Laboratory studies show:

Cholesterol, total	290 mg/dL
HDL-cholesterol	40 mg/dL
LDL-cholesterol	190 mg/dL
Triglycerides	350 mg/dL

Treatment with atorvastatin and losartan is initiated. Which of the following serum findings is most likely to occur in this patient?

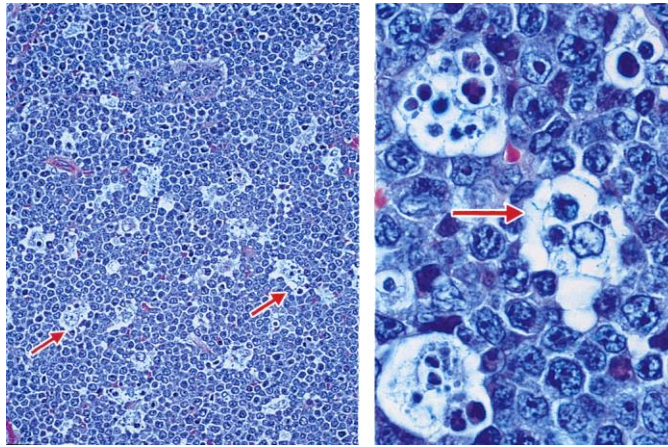
	HDL-cholesterol	Triglycerides
(A)	Decreased	decreased
(B)	Decreased	increased
(C)	Increased	decreased
(D)	Increased	increased
(E)	No change	no change

-
95. A 73-year-old woman comes to the physician because of a 2-month history of diffuse weakness and tingling of her arms and legs. Neurologic examination shows weakness of the extensor and flexor muscles of the lower extremities. Knee and ankle deep tendon reflexes are exaggerated. Sensation to vibration and position is decreased in all extremities, but the decrease is more prominent in the lower extremities than in the upper extremities. This patient most likely has a deficiency of which of the following vitamins?

- (A) Niacin
- (B) Vitamin B₁ (thiamine)
- (C) Vitamin B₂ (riboflavin)
- (D) Vitamin B₆ (pyridoxine)
- (E) Vitamin B₁₂ (cyanocobalamin)

96. A 15-year-old girl comes to the physician because of a 3-month history of acne. Breast and pubic hair development began at the age of 12 years. Menarche occurred at the age of 14 years. Physical examination shows scattered open and closed comedones over the cheeks and forehead. Breast and pubic hair development are Tanner stage 5. Which of the following is the most likely underlying cause of this patient's acne?

- (A) Decreased parasympathetic stimulation to the sebaceous glands
- (B) Increased estrogen stimulation of the sebaceous glands
- (C) Increased responsiveness of the sebaceous glands to follicle-stimulating hormone
- (D) Increased sympathetic stimulation to the sebaceous glands
- (E) Stimulation of the sebaceous glands by androgens



97. A 4-year-old boy from Brazil is brought to the physician because of a 1-week history of painless swelling of his jaw and pressure around his eyes. He is at the 80th percentile for height and weight. Physical examination shows a single 12×10 -cm lesion in the right side of the jaw with diffuse limits and irregular edges. Photomicrographs of an incisional biopsy specimen of the lesion are shown. Based on these findings, which of the following processes is most likely occurring in the region indicated by the arrows?
- (A) Apoptosis
 - (B) Necrosis
 - (C) Oncosis
 - (D) Ostosis
 - (E) Symptosis
-
98. A 51-year-old man comes to the office because of a 6-month history of a lump on his tongue that is interfering with his speech and eating; he also has had a 6.8-kg (15-lb) weight loss during this period. He has smoked 1 pack of cigarettes daily and has consumed six 12-oz bottles of beer on weekend nights during the past 30 years. His vital signs are within normal limits. Physical examination shows a 1.5-cm mass on the apex of the tongue. Further evaluation of the mass confirms squamous cell carcinoma. It is most appropriate to evaluate which of the following lymph nodes first for evidence of metastasis in this patient?
- (A) Inferior deep cervical
 - (B) Parotid
 - (C) Retropharyngeal
 - (D) Submental
 - (E) Superior deep cervical
99. A 15-year-old boy is brought to the emergency department by his parents because of a 2-hour history of confusion and agitation. He also has had fever, headache, stiff neck, and vomiting since he returned from summer camp 2 days ago. His parents say he does not use illicit drugs. On arrival, he is combative and there is evidence of hallucinations. His temperature is 40°C (104°F), pulse is 80/min, respirations are 17/min, and blood pressure is 100/70 mm Hg. A lumbar puncture is performed. Results of cerebrospinal fluid analysis show cysts and trophozoites. The most likely portal of pathogen entry into this patient's central nervous system is which of the following?
- (A) Cavernous sinus
 - (B) Facial nerve
 - (C) Frontal sinus
 - (D) Mastoid sinus
 - (E) Olfactory nerve
 - (F) Trigeminal nerve

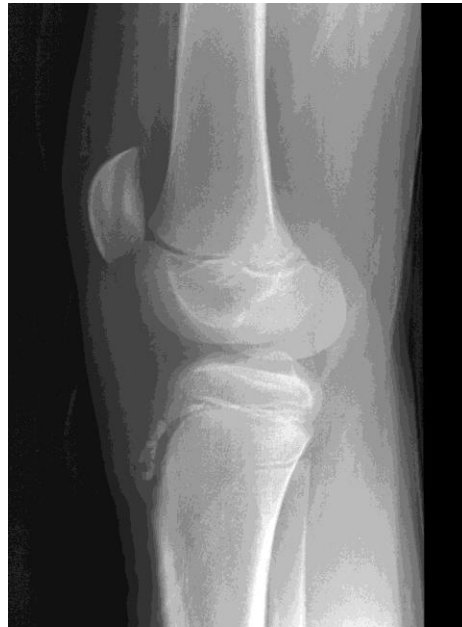100. A 17-year-old boy is brought to the emergency department 30 minutes after being found with a "blank stare" and flat facial expression at a party. His pulse is 72/min, and blood pressure is 104/68 mm Hg. He is sitting upright and appears catatonic. Physical examination shows rigidity. During the examination, he becomes hostile and attempts to assault the physician. This patient most likely ingested which of the following drugs?
- (A) Cocaine
 - (B) Diazepam
 - (C) Methamphetamine
 - (D) Oxycodone
 - (E) PCP (phencyclidine)
101. A placebo-controlled clinical trial is conducted to assess whether a new antihypertensive drug is more effective than standard therapy. A total of 5000 patients with essential hypertension are enrolled and randomly assigned to one of two groups: 2500 patients receive the new drug and 2500 patients receive placebo. If the alpha is set at 0.01 instead of 0.05, which of the following is the most likely result?
- (A) Significant findings can be reported with greater confidence
 - (B) The study will have more power
 - (C) There is a decreased likelihood of a Type II error
 - (D) There is an increased likelihood of statistically significant findings
 - (E) There is an increased likelihood of a Type I error
102. A 17-year-old girl is brought to the physician by her mother because she has not had a menstrual period for 6 months. The patient is unconcerned about the lack of menses. Menarche occurred at the age of 12 years, and menses had occurred at regular 28-day intervals until they became irregular 1 year ago. She is a member of her high school gymnastics team. She appears emaciated. She is 163 cm (5 ft 4 in) tall and weighs 40 kg (88 lb); BMI is 15 kg/m². Her pulse is 54/min, and blood pressure is 80/50 mm Hg. Which of the following is the most likely cause of this patient's amenorrhea?
- (A) Hyperthyroidism
 - (B) Hypogonadotropic hypogonadism
 - (C) Hypothyroidism
 - (D) Polycystic ovarian syndrome
 - (E) Prolactinoma
103. A male stillborn is delivered at 32 weeks' gestation to a 30-year-old woman. The pregnancy was complicated by oligohydramnios. Examination of the stillborn shows the absence of a urethral opening. Which of the following additional findings is most likely in this stillborn?
- (A) Congenital diaphragmatic hernia
 - (B) Intralobar sequestration
 - (C) Pulmonary hypoplasia
 - (D) Situs inversus
 - (E) Tracheoesophageal fistula

104. A 6-day-old breast-fed boy is brought to the emergency department by his mother because of poor weight gain and irritability since delivery, and a 2-hour history of vomiting. Physical examination shows jaundice and hepatomegaly. A reducing substance test result of the urine is positive, and a glucose oxidase test result is negative. The concentration of which of the following metabolites in liver is most likely increased in this patient?
- (A) Fructose 1,6-bisphosphate
 - (B) Galactose 1-phosphate
 - (C) Glucose 1-phosphate
 - (D) Glucose 6-phosphate
105. A 25-year-old man is brought to the emergency department because of a 6-day history of fever, severe muscle pain, and diffuse, painful swelling of his neck, underarms, and groin area. The symptoms began after returning from a camping trip in New Mexico. He appears ill and lethargic and can barely answer questions. His temperature is 39.2°C (102.5°F), pulse is 120/min, respirations are 22/min, and blood pressure is 110/70 mm Hg. Physical examination shows generalized scattered black maculae. Examination of the right upper extremity shows an erythematous, solid, tender mass on the underside of the upper extremity just above the elbow; the mass is draining blood and necrotic material. The most effective antibiotic for this patient's disorder will interfere with which of the following cellular processes or enzymes?
- (A) Cell wall synthesis
 - (B) DNA helicase
 - (C) Glucuronosyltransferase
 - (D) Proteasomal degradation
 - (E) Ribosomal assembly
 - (F) Tetrahydrofolate reductase
106. A 45-year-old man is brought to the clinic by his wife because of a 6-month history of progressive weakness; he also has had dysphagia and a 4.5-kg (10-lb) weight loss during this period. He has had to use a wheelchair during the past 3 weeks because of the weakness. He has no other history of major medical illness and takes no medications. He is a former financial analyst and has no known toxin exposures. He does not smoke or drink alcoholic beverages. He is 183 cm (6 ft) tall and now weighs 68 kg (150 lb); BMI is 20 kg/m². His temperature is 37.0°C (98.6°F), pulse is 88/min, respirations are 18/min, and blood pressure is 138/78 mm Hg. He is mentally alert. Physical examination shows muscle fasciculations of the upper extremities and weakness of the lower extremities. The remainder of the physical examination is most likely to show which of the following additional findings in this patient?
- (A) Atrophy
 - (B) Decreased visual acuity
 - (C) Loss of proprioception
 - (D) Presence of palmomental reflex
 - (E) Ptosis
107. A new severe respiratory illness caused by a newly identified virus is discovered. Which of the following properties of a killed vaccine relative to a live vaccine is the most appropriate rationale for developing a killed vaccine for this illness?
- (A) Avoids the concern for reversion to virulence
 - (B) Develops more rapid protective immunity
 - (C) Is less likely to require subsequent boosters for lifelong immunity
 - (D) Is most likely to generate mucosal immunity
 - (E) Requires little safety monitoring to ensure inactivation

108. A 33-year-old woman comes to the physician because of a 2-day history of mild nausea, increased urinary urgency and frequency, and constipation. She also has had a 4.5-kg (10-lb) weight loss during the past 2 weeks and a 3-week history of vaginal bleeding. Pelvic examination shows a nodular cervix with an irregular, friable posterior lip, and a rock-hard, irregular, immobile pelvic mass that extends across the pelvis. Examination of biopsy specimens from the cervix and anterior wall of the vagina show well-differentiated keratinizing squamous cell carcinoma. Which of the following best describes the pathogenesis of this patient's disease?
- (A) Inactivation of cellular p53
 - (B) Insertion of viral promoters adjacent to cellular growth factor genes
 - (C) Specialized transduction
 - (D) Transactivation of cellular growth factor genes by *TAX*
 - (E) Translocation of *CMYC* to an Ig gene promoter
109. A 54-year-old woman with a 40-year history of type 1 diabetes mellitus comes to the office for a follow-up examination. She is receiving hemodialysis for end-stage renal disease while awaiting a kidney transplant. As part of her regimen, she also receives regular injections of a drug that induces reticulocyte release from the bone marrow and stimulates a cytokine receptor that signals via the JAK/STAT pathway. This patient is most likely receiving which of the following drugs?
- (A) Erythropoietin
 - (B) Filgrastim
 - (C) Interleukin-2 (IL-2)
 - (D) Platelet-derived growth factor
 - (E) Sargramostim
110. During a clinical study examining the effects of exercise, men between the ages of 20 and 30 years are evaluated during a 15-minute session on a treadmill. The average pulse for the last 2 minutes of the session is 175/min. During the last minute of exercise, various measurements are taken. Compared with the measurement before the session, which of the following is most likely to be decreased?
- (A) Cardiac output
 - (B) Oxygen consumption
 - (C) Pulse pressure
 - (D) Stroke volume
 - (E) Systolic blood pressure
 - (F) Total peripheral resistance
111. An 8-year-old boy is brought to the office by his mother because of a 3-day history of fever, sore throat, and itchy eyes. He just returned from a weeklong summer camp that included hiking trips and swimming lessons in the camp-owned swimming pool. He has no history of major medical illness and receives no medications. He appears tired. His temperature is 39.4°C (102.9°F); other vital signs are within normal limits. Physical examination shows conjunctival injection and discharge and oropharyngeal erythema. The public health department reports an outbreak of similar symptoms among the other campers and camp volunteers. Which of the following is the most likely cause of this patient's symptoms?
- (A) Adenovirus
 - (B) Cytomegalovirus
 - (C) Epstein-Barr virus
 - (D) Influenza virus
 - (E) West Nile virus

112. A 44-year-old woman comes to the office because of a 10-month history of wide red streaks over her lower trunk and significant weight gain in her face and abdomen. Although her appetite has increased, she has noticed that her arms and legs have become thinner. Which of the following additional findings are most likely in this patient?

- (A) Hyperkalemia and numerous bruises
- (B) Hypertension and muscle weakness
- (C) Hypocalcemia and hyperglycemia
- (D) Hypoglycemia and fat pads between the scapulae
- (E) Jaundice and thinning of the skin



113. A 12-year-old boy is brought to the physician by his mother because of a 1-month history of pain below the left knee. His mother says, "He can usually walk around, but he hasn't been able to play in any of his soccer games since this all began." Examination of the left knee shows warmth, swelling, and tenderness. An x-ray of the knee is shown. Which of the following structures is attached to the abnormal anterior tibial area?

- (A) Anterior cruciate ligament
 - (B) Gastrocnemius muscle
 - (C) Patellar ligament
 - (D) Popliteus muscle
 - (E) Posterior cruciate ligament
 - (F) Soleus muscle
-

114. A 65-year-old retired man comes to the office for a health maintenance examination. He has no history of major medical illness and takes no medications. He lives in a single-family home with his cat and dog. He spends much of his time in his basement woodworking shop. He does not smoke. His temperature is 37.0°C (98.6°F), pulse is 84/min, respirations are 12/min, and blood pressure is 138/88 mm Hg. Physical examination shows no cyanosis. The lungs are clear. Cardiac examination shows no abnormalities. Extremity examination shows no edema. The patient wishes to mitigate his risk for pulmonary disease. This patient is at increased risk for lung cancer because of which of the following environmental exposures?
- (A) Indoor cleaning chemicals
 - (B) Pet dander
 - (C) Polyurethane
 - (D) Radon
 - (E) Sawdust
115. A 54-year-old man comes to the physician for a follow-up examination 10 days after undergoing a stereotactic brain operation to remove a small tumor. The operation was successful. During the procedure, he was under conscious sedation. The patient recalls that at one point during the operation he experienced a sudden, intense feeling of overwhelming fear. Which of the following areas of the brain was most likely stimulated at that time?
- (A) Amygdala
 - (B) Hippocampus
 - (C) Mammillary body
 - (D) Prefrontal cortex
 - (E) Thalamus
116. A 30-year-old woman comes to the physician because of a 2-day history of abdominal pain. She has a history of recurrent upper respiratory tract infections, sinusitis, and pancreatitis. She has thick nasal secretions. She says that her sweat is salty and crystallizes on her skin. Her vital signs are within normal limits. Physical examination shows epigastric tenderness. Genetic testing for the 36 most common mutations shows a detectable mutation (G551D) in one allele of the *CFTR* gene. Which of the following best explains this patient's clinical phenotype?
- (A) Loss of heterozygosity of the *CFTR* gene has occurred in the pancreas
 - (B) Only one G551D allele is needed in *CFTR*
 - (C) The patient is a *CFTR* obligate carrier
 - (D) The patient's *CFTR* mutation is unrelated to her clinical phenotype
 - (E) The second *CFTR* mutation was not detected by the testing obtained
117. A 74-year-old man with mild chronic obstructive pulmonary disease comes to the physician for a follow-up examination. Current medications include a short-acting β_2 -adrenergic agonist by metered-dose inhaler as needed. Physical examination shows no abnormalities. At the end of the examination, he tells the physician, "I enjoy coming to see you because you remind me of my daughter. She died 35 years ago this month." He has been a patient of this physician for 5 years. Which of the following is the most appropriate response by the physician?
- (A) "I may have to refer you to another physician who doesn't remind you of your daughter so you can focus more on your medical condition and its treatment."
 - (B) "I'd like to refer you to a grief counselor so that you can work out your unresolved feelings about your daughter's death."
 - (C) "I'm sorry you lost your daughter. Unfortunately, since we only have a limited amount of time, we must now move on to your medical condition."
 - (D) "That makes me feel a little uncomfortable. I hope you understand."
 - (E) "You must miss your daughter very much. Tell me about her."

118. A 9-month-old boy is brought to the office by his mother for a well-child examination. He was born at 32 weeks' gestation because of spontaneous rupture of membranes. Growth and development are appropriate for age. His mother says he can sit without support and is interactive. She is concerned that he still takes two to three 1-hour naps daily. He goes to sleep at 7 PM and awakens at 7 AM. She says he also awakens and cries at least once nightly and settles back to sleep after drinking a bottle of formula. Physical examination shows no abnormalities. Which of the following is the most likely explanation for this patient's sleep pattern?
- (A) Gastroesophageal reflux
 - (B) Hypoglycemia
 - (C) Obstructive sleep apnea
 - (D) Parasomnia
 - (E) Normal development
119. A 32-year-old man comes to the office because of a 2-year history of abnormal movements of his hands that are worse when he feels angry or depressed. His maternal grandmother and mother, both now deceased, had similar symptoms with onset at the ages of 53 years and 42 years, respectively. Neurologic examination shows normal muscle strength, bulk, and tone. There is no intention tremor or dysmetria. Sensation is intact. He is unable to fix his gaze on one point or protrude his tongue for more than 30 seconds. Deep tendon reflexes are hyperactive. Mental status examination shows no abnormalities. This patient most likely has an anatomic abnormality in which of the following locations?
- (A) Basal ganglia
 - (B) Cerebellum
 - (C) Dorsal spinal column
 - (D) Frontal lobe
 - (E) Lateral spinal column

ANSWER FORM FOR USMLE STEP 1 SAMPLE TEST QUESTIONS

Block 1 (Questions 1–40)

1.	___	11.	___	21.	___	31.	___
2.	___	12.	___	22.	___	32.	___
3.	___	13.	___	23.	___	33.	___
4.	___	14.	___	24.	___	34.	___
5.	___	15.	___	25.	___	35.	___
6.	___	16.	___	26.	___	36.	___
7.	___	17.	___	27.	___	37.	___
8.	___	18.	___	28.	___	38.	___
9.	___	19.	___	29.	___	39.	___
10.	___	20.	___	30.	___	40.	___

Block 2 (Questions 41–80)

41.	___	51.	___	61.	___	71.	___
42.	___	52.	___	62.	___	72.	___
43.	___	53.	___	63.	___	73.	___
44.	___	54.	___	64.	___	74.	___
45.	___	55.	___	65.	___	75.	___
46.	___	56.	___	66.	___	76.	___
47.	___	57.	___	67.	___	77.	___
48.	___	58.	___	68.	___	78.	___
49.	___	59.	___	69.	___	79.	___
50.	___	60.	___	70.	___	80.	___

Block 3 (Questions 81–119)

81.	___	91.	___	101.	___	111.	___
82.	___	92.	___	102.	___	112.	___
83.	___	93.	___	103.	___	113.	___
84.	___	94.	___	104.	___	114.	___
85.	___	95.	___	105.	___	115.	___
86.	___	96.	___	106.	___	116.	___
87.	___	97.	___	107.	___	117.	___
88.	___	98.	___	108.	___	118.	___
89.	___	99.	___	109.	___	119.	___
90.	___	100.	___	110.	___		

ANSWER KEY FOR USMLE STEP 1 SAMPLE TEST QUESTIONS

Block 1 (Questions 1–40)

1. B	11. A	21. C	31. C
2. A	12. C	22. F	32. A
3. C	13. B	23. A	33. C
4. C	14. C	24. B	34. A
5. A	15. E	25. B	35. B
6. C	16. D	26. E	36. B
7. C	17. A	27. E	37. A
8. C	18. D	28. E	38. E
9. A	19. A	29. C	39. E
10. B	20. A	30. C	40. B

Block 2 (Questions 41–80)

41. B	51. D	61. E	71. E
42. A	52. E	62. E	72. D
43. A	53. C	63. B	73. A
44. D	54. A	64. B	74. A
45. B	55. E	65. B	75. B
46. E	56. B	66. D	76. C
47. D	57. C	67. D	77. C
48. D	58. A	68. D	78. B
49. C	59. C	69. E	79. A
50. D	60. A	70. E	80. D

Block 3 (Questions 81–119)

81. B	91. C	101. A	111. A
82. D	92. C	102. B	112. B
83. B	93. A	103. C	113. C
84. E	94. C	104. B	114. D
85. A	95. E	105. E	115. A
86. D	96. E	106. A	116. E
87. D	97. A	107. A	117. E
88. C	98. D	108. A	118. E
89. B	99. E	109. A	119. A
90. D	100. E	110. F	